

Intraductal Epithelial Proliferations

(Intraductal Diagnostic Dilemmas)

Laura C. Collins, M.D.

Vice Chair of Anatomic Pathology

Director of Breast Pathology

Professor of Pathology

Beth Israel Deaconess Medical Center

and Harvard Medical School

Boston, MA

Beth Israel Lahey Health



Beth Israel Deaconess
Medical Center



HARVARD MEDICAL SCHOOL
TEACHING HOSPITAL

Outline

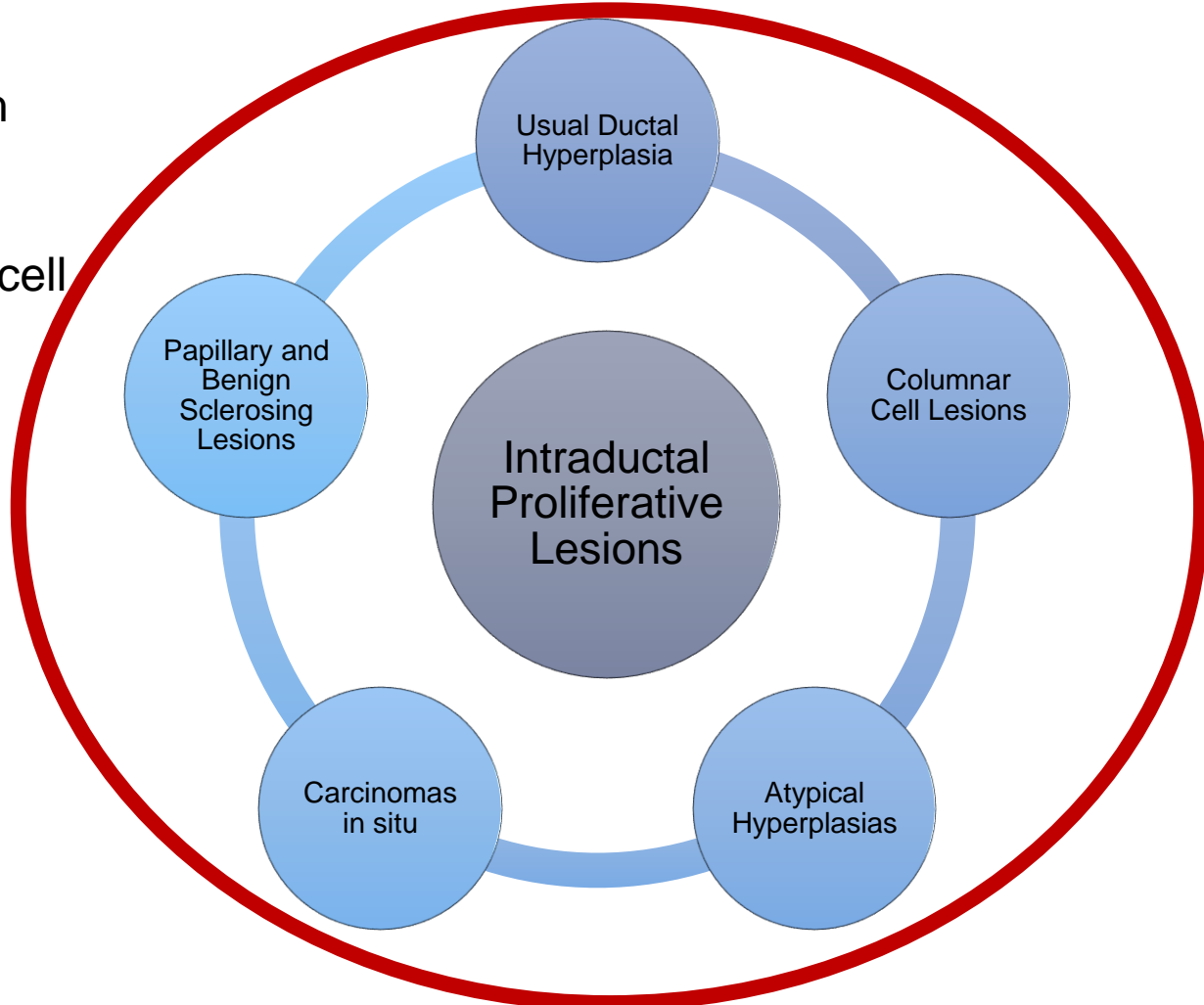
Discuss a diagnostic approach to intraductal proliferations of the breast

- UDH
- CCL
- ADH
- DCIS

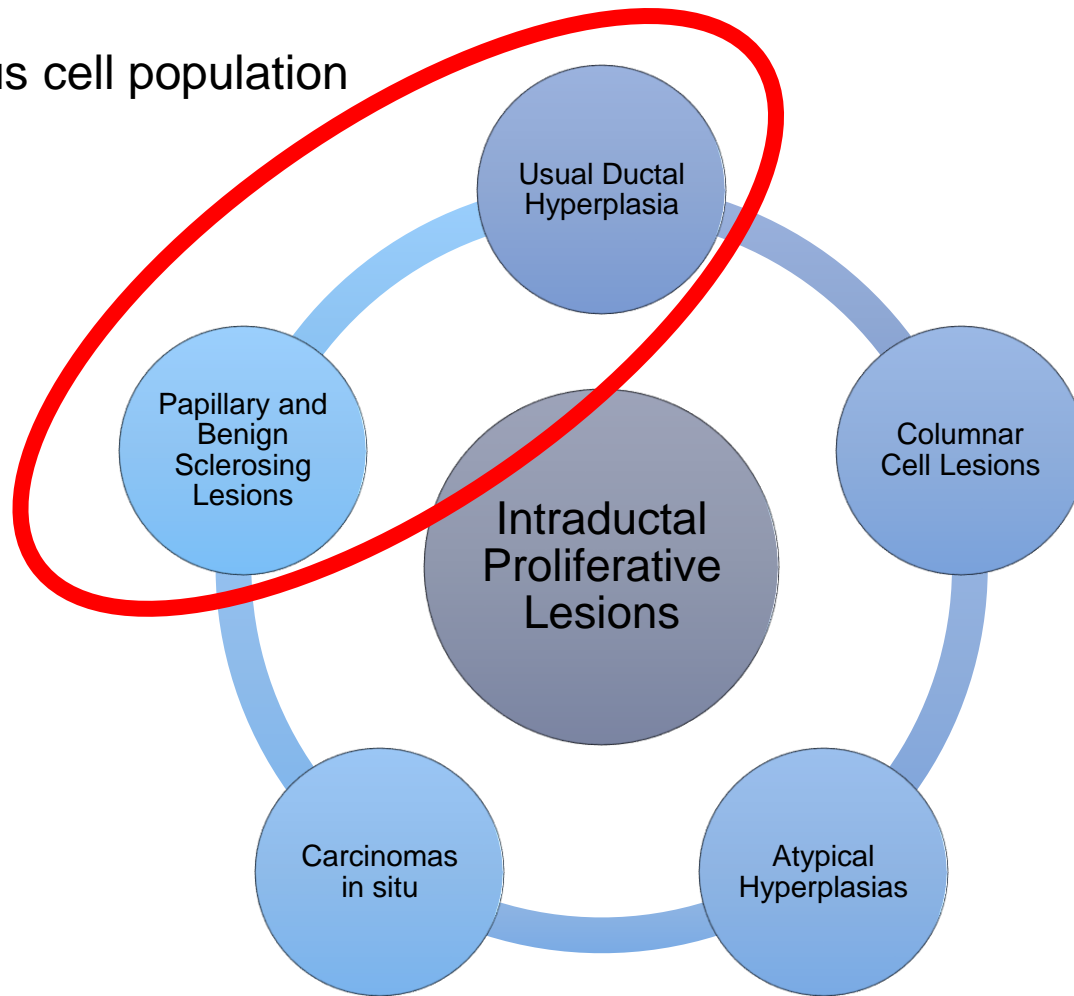
Discuss differential diagnoses and ancillary studies that can help inform diagnosis

Proliferation
contained with
the duct

Myoepithelial cell
marker +



Heterogeneous cell population
CK5/6 +
ER variably +



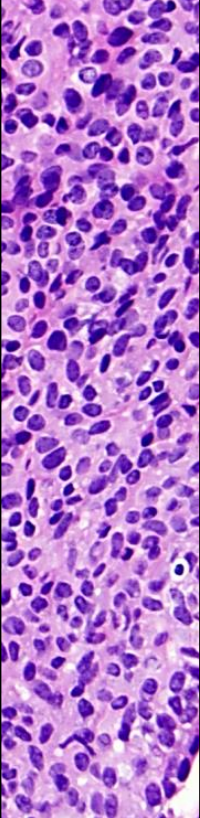
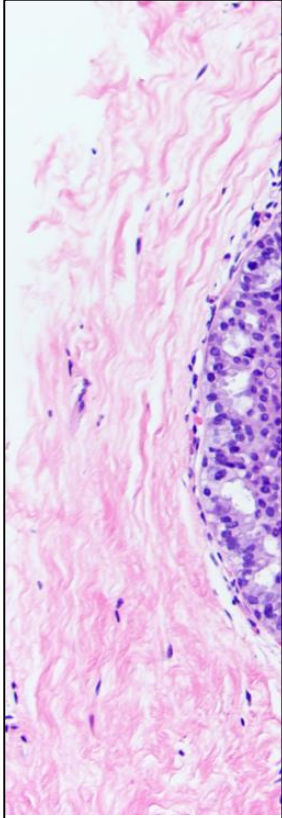
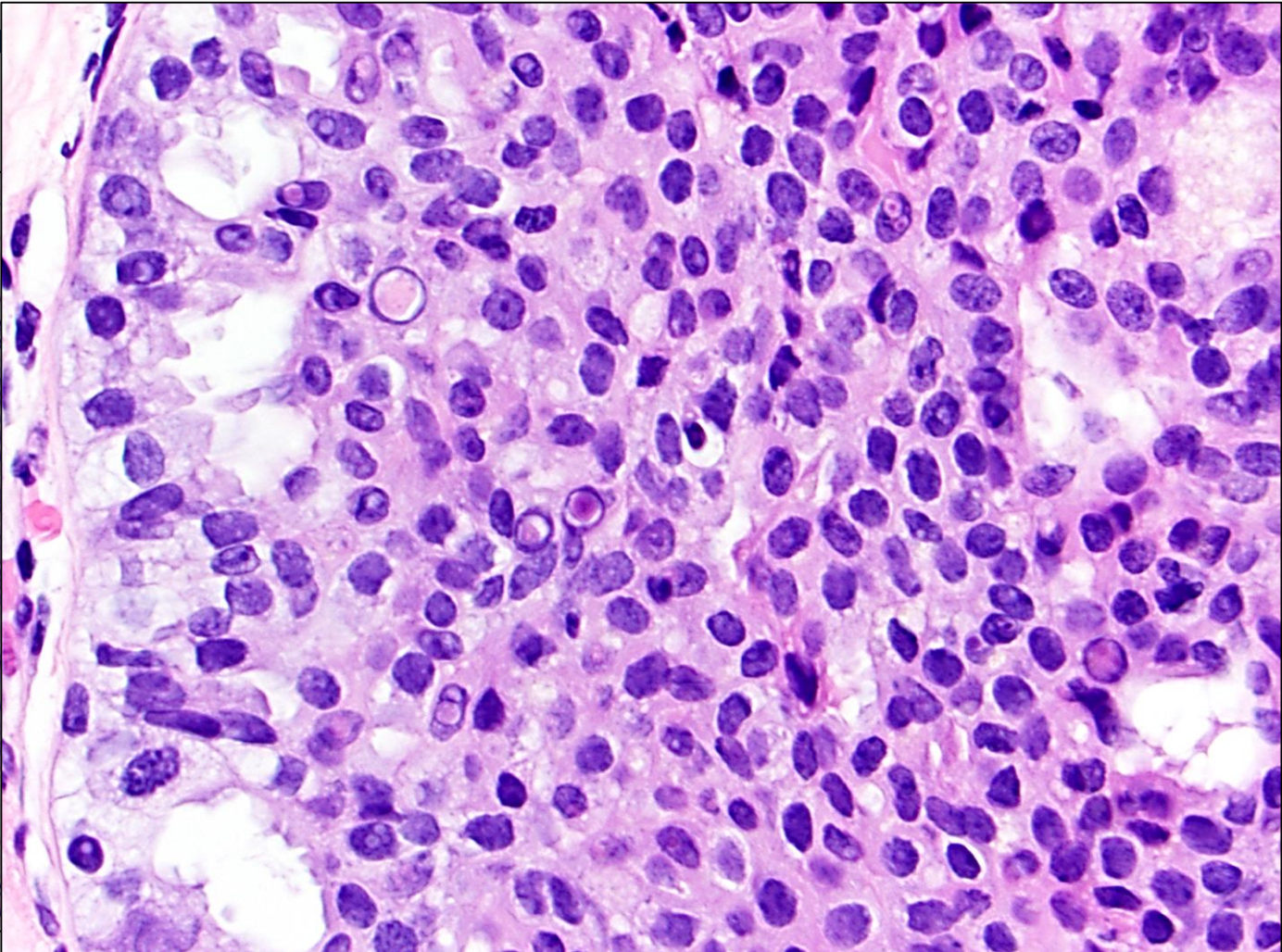
Usual Ductal Hyperplasia

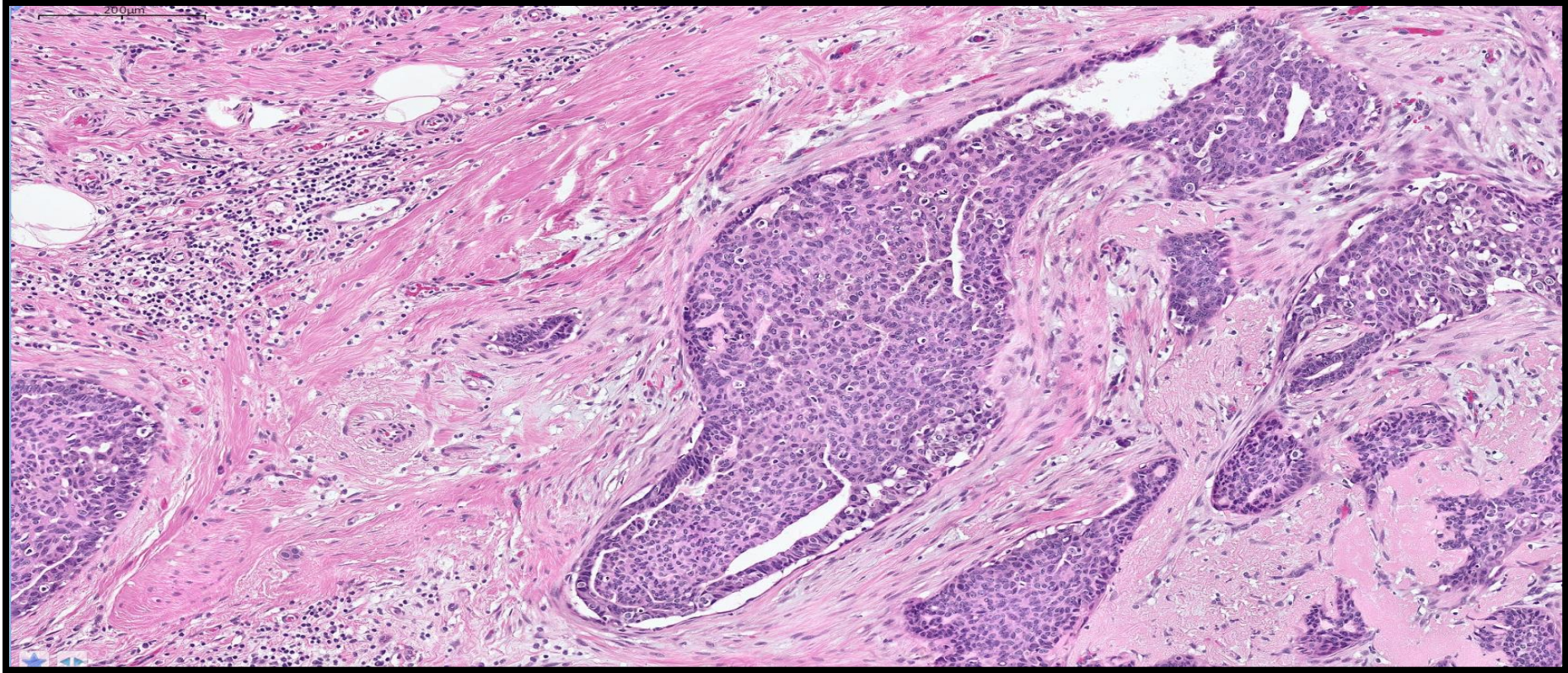
Key Features of UDH

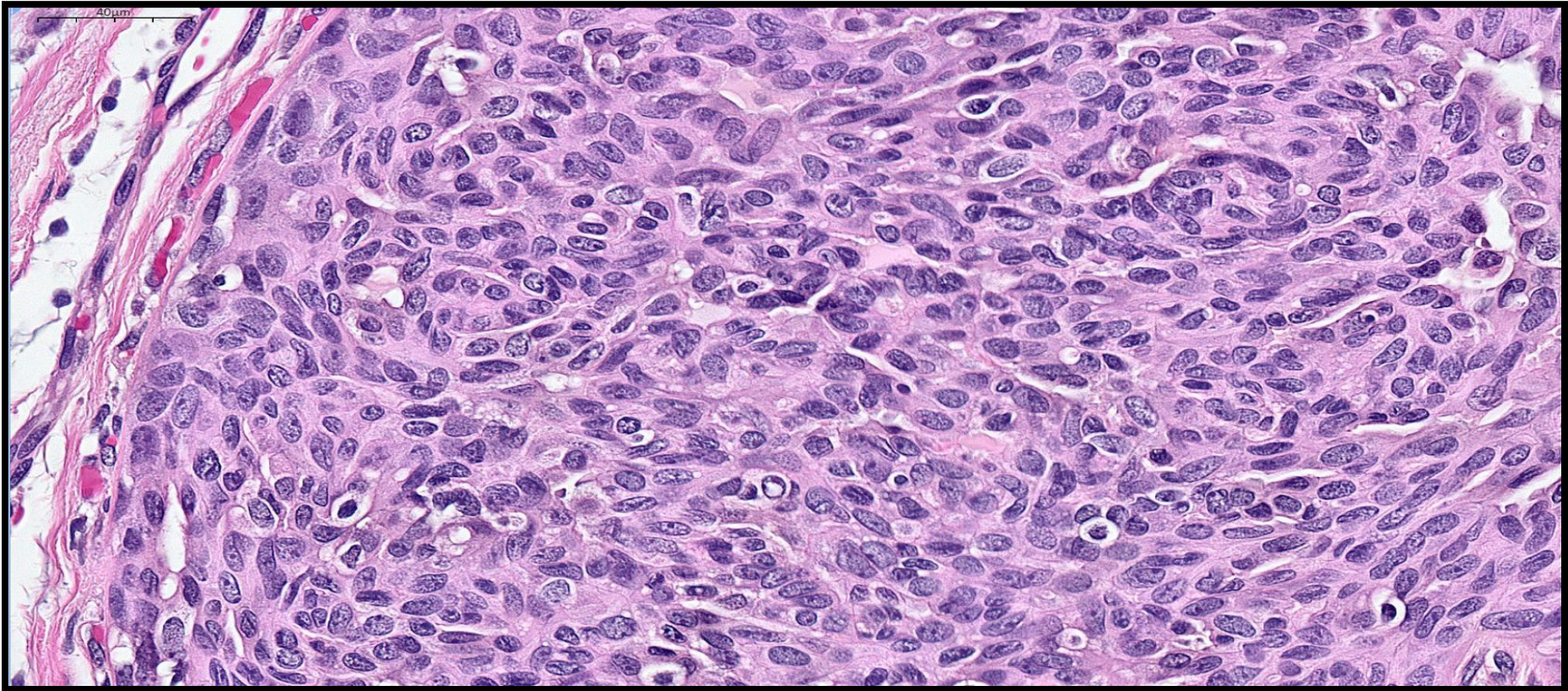
Biopsy Interpretation
of the Breast, 2018

Cytologic Features	Heterogeneous cell population
	Variation in cell size, shape and orientation
	Cell borders poorly defined
	Variation in size, shape and placement of nuclei, with areas of overlapping, nuclear grooves and intranuclear inclusions
Architectural Features	Solid, fenestrated or micropapillary
	Lumens irregular, variable in size and shape, often slit-like and displaced to the periphery without polarization of cells around the lumens
	Bridges stretched or twisted with central attenuation

Usual Du







Adjunctive IHC

UDH

Mixed population of cells that express low and high molecular weight keratins (the latter often in a heterogeneous or mosaic pattern)

DCIS

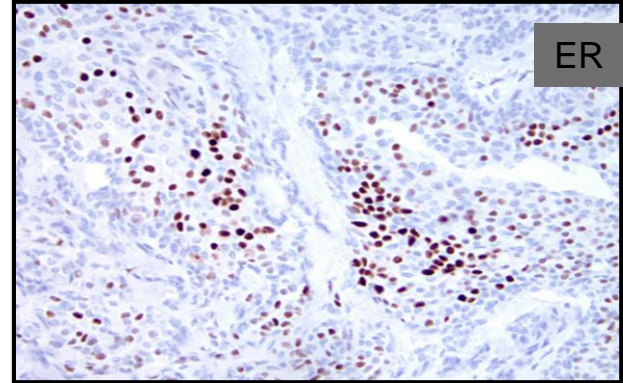
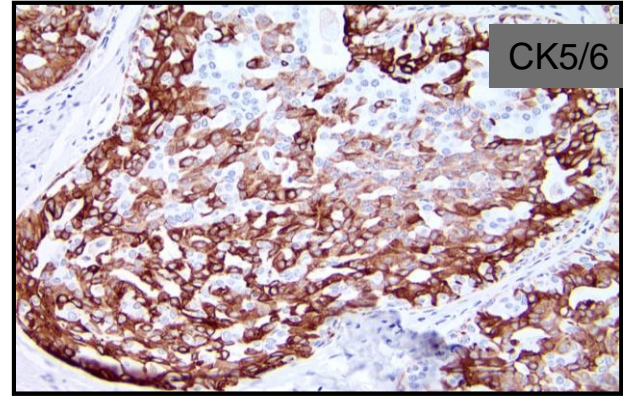
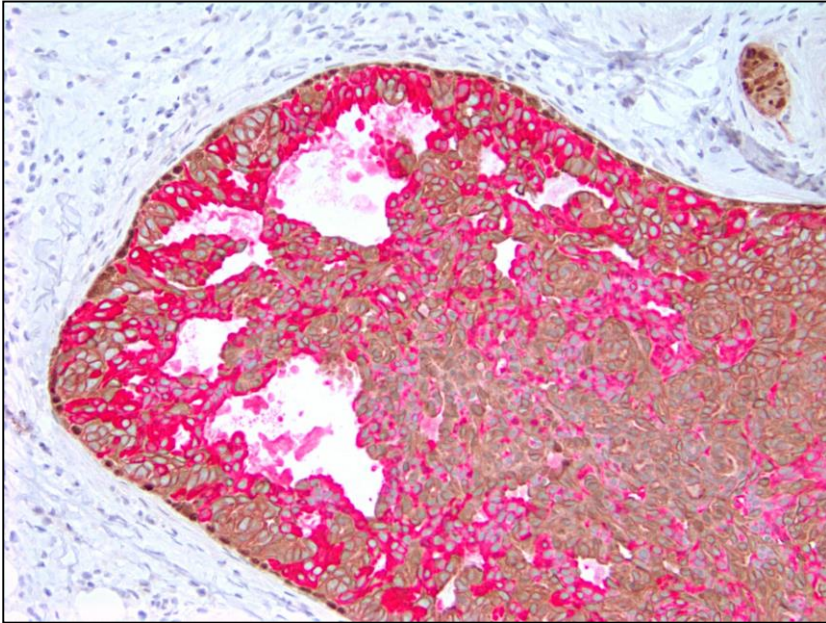
Monoclonal population of cells that express low but *NOT* high molecular weight keratins

Immunohistochemical Features

LMK-red cytoplasmic

HMK-brown cytoplasmic

p63-brown nuclear



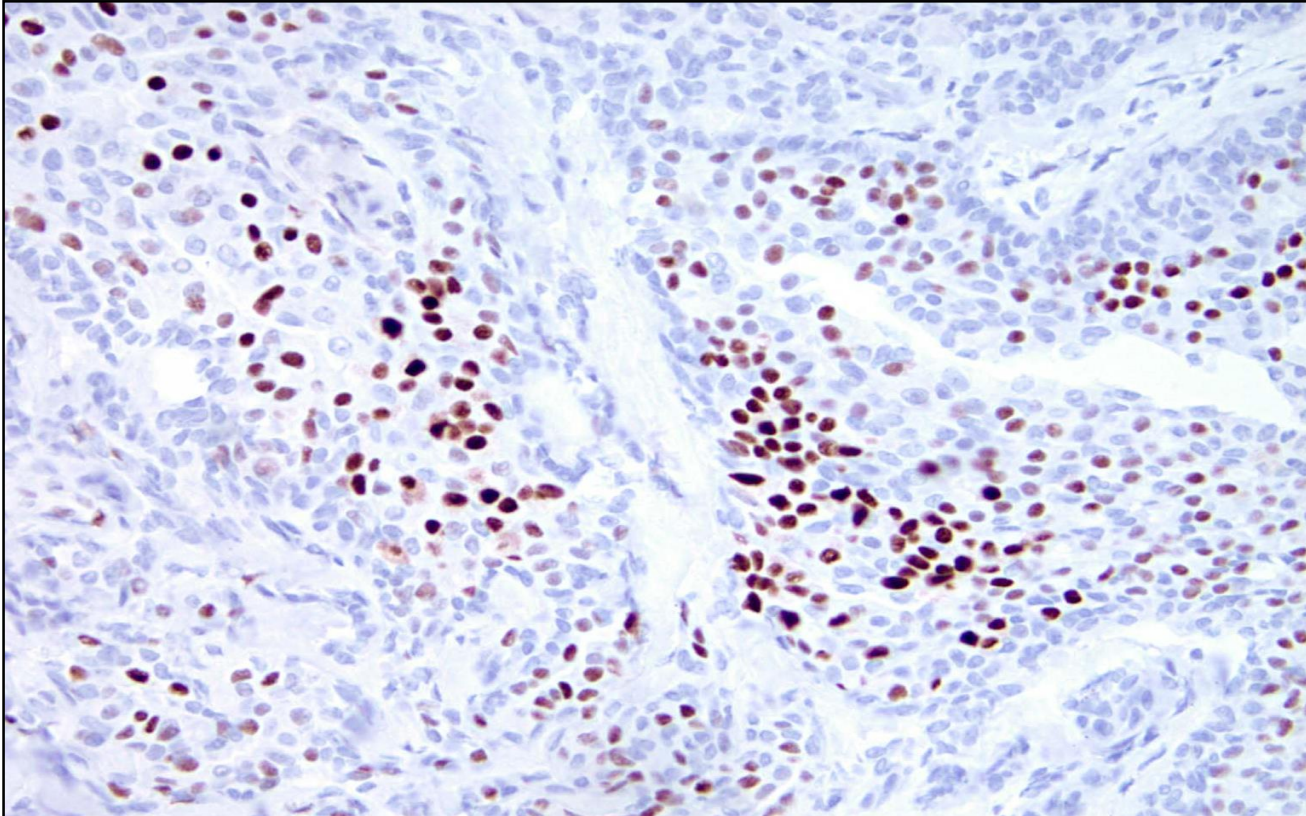
UDH

- Mixed population of cells with heterogeneous expression of ER

DCIS

- Monoclonal population of cells with strong, diffuse expression of ER
- Exceptions: High grade and/or apocrine DCIS which may be ER negative

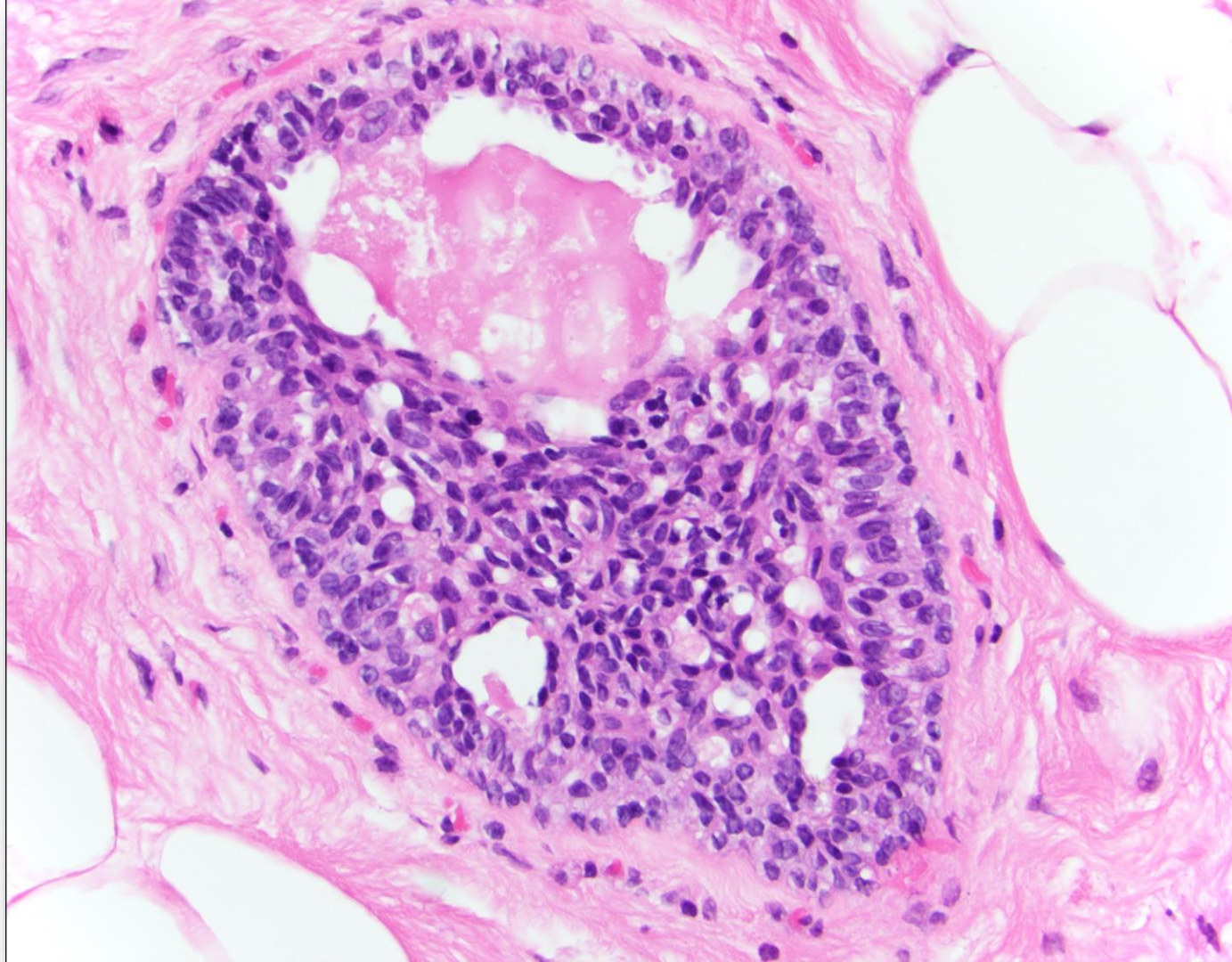
Estrogen Receptor Staining in UDH

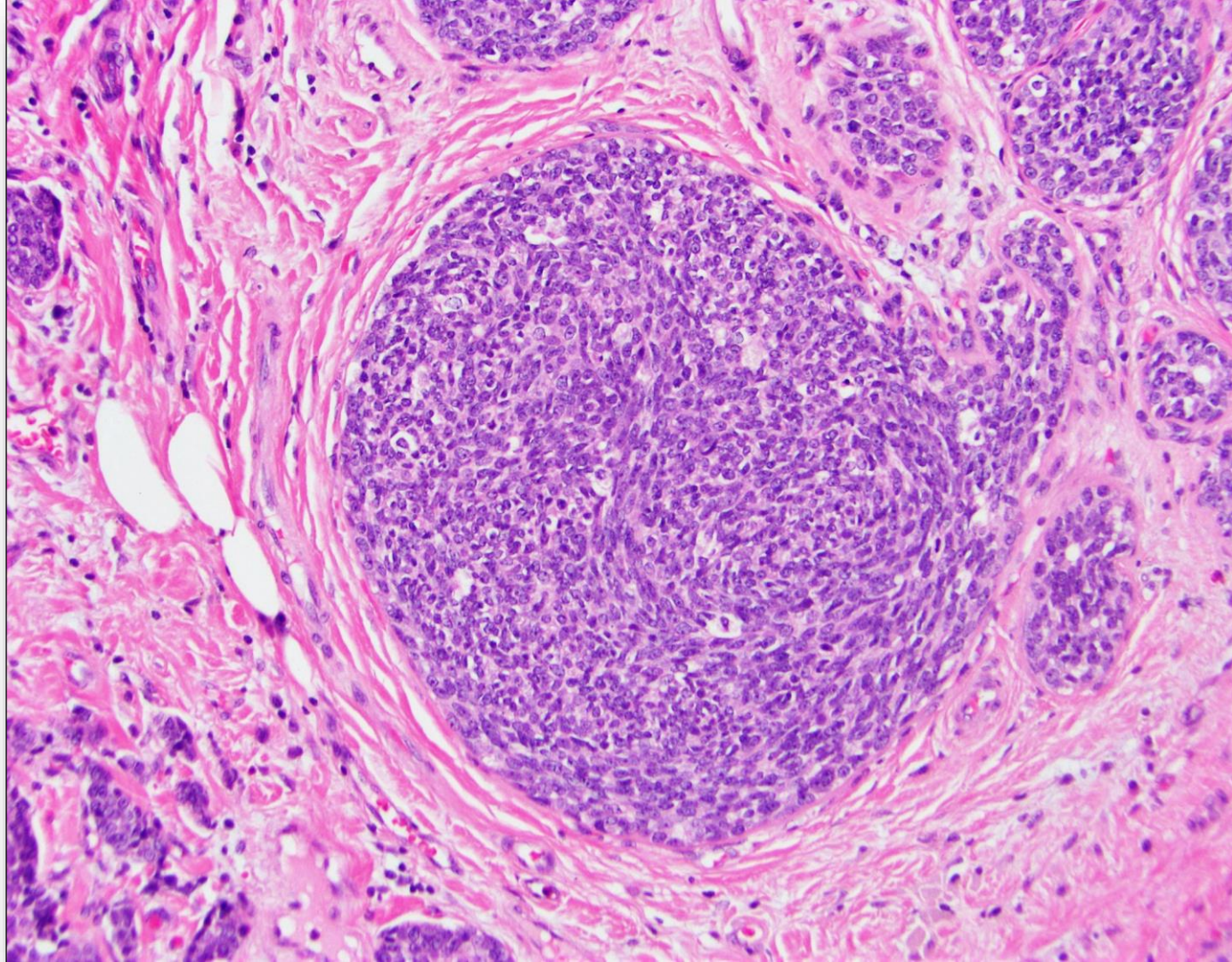


UDH vs. DCIS

Points to consider:

- Differential is most often with intermediate nuclear grade DCIS
- Micropapillary pattern may also be a challenge
- Consider imaging target
- Use IHC in problematic cases (CK5/6 and ER)





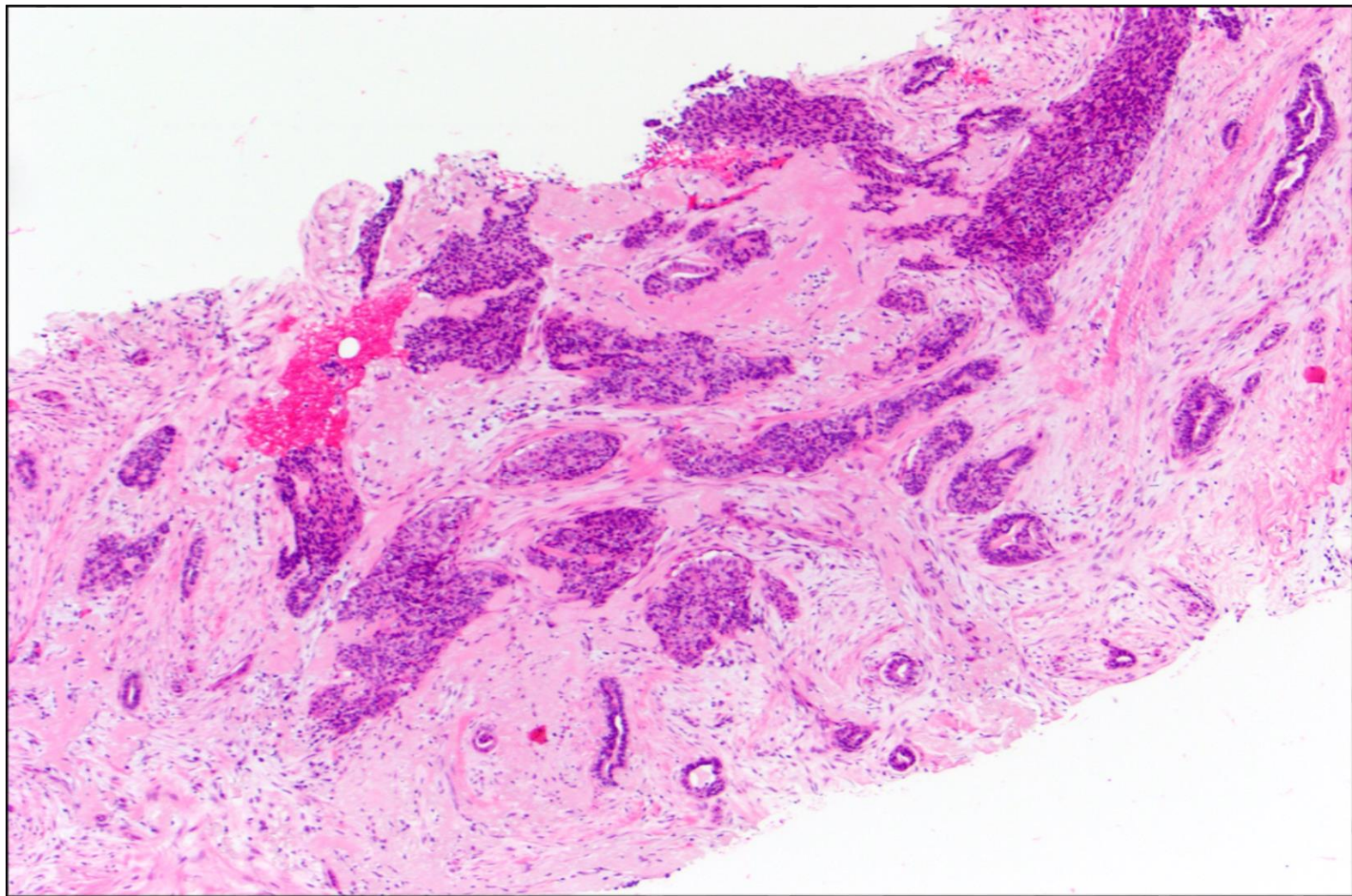
Potential Pitfalls with UDH

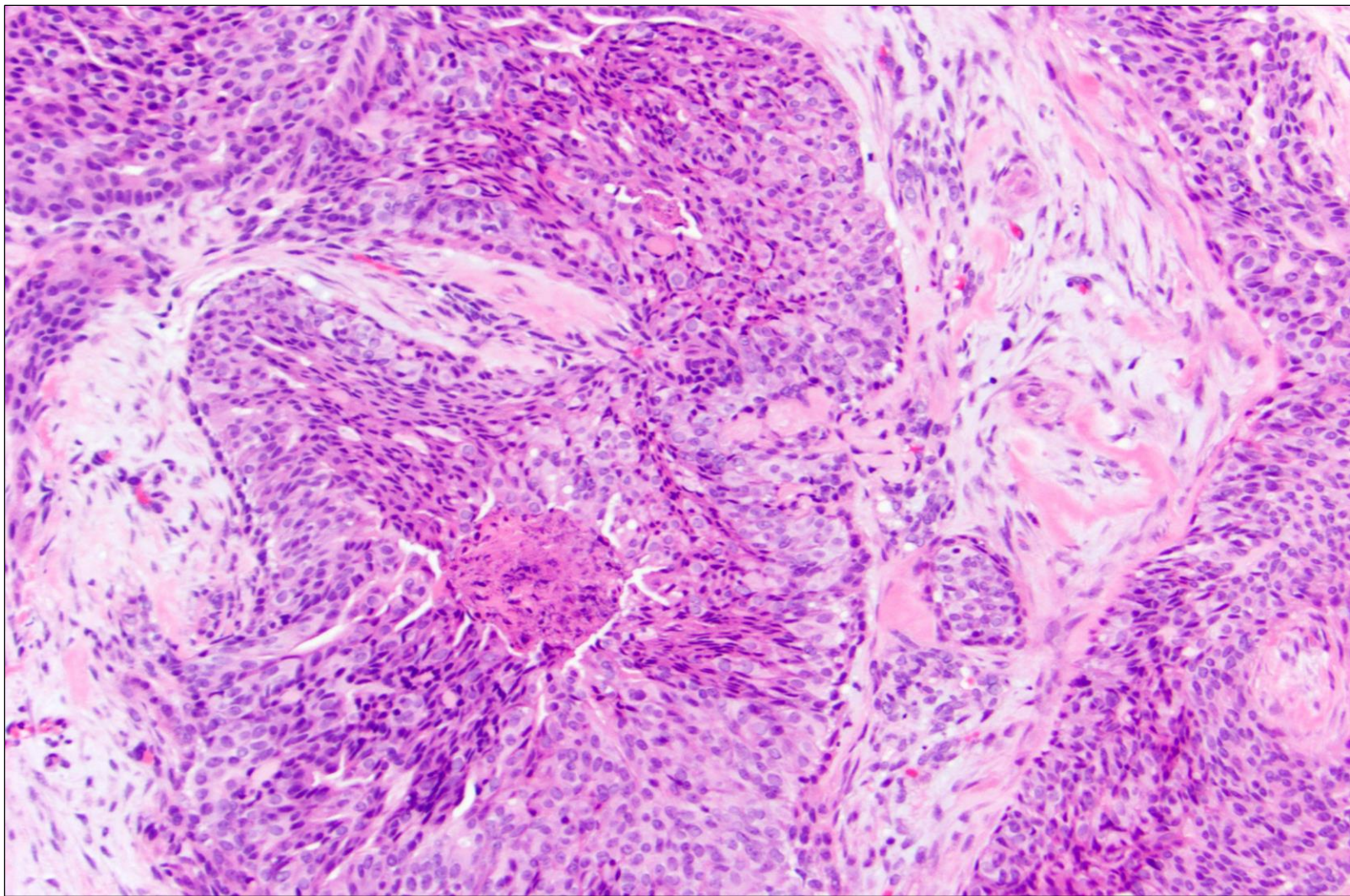
Presence of necrosis can lead to misinterpretation as DCIS

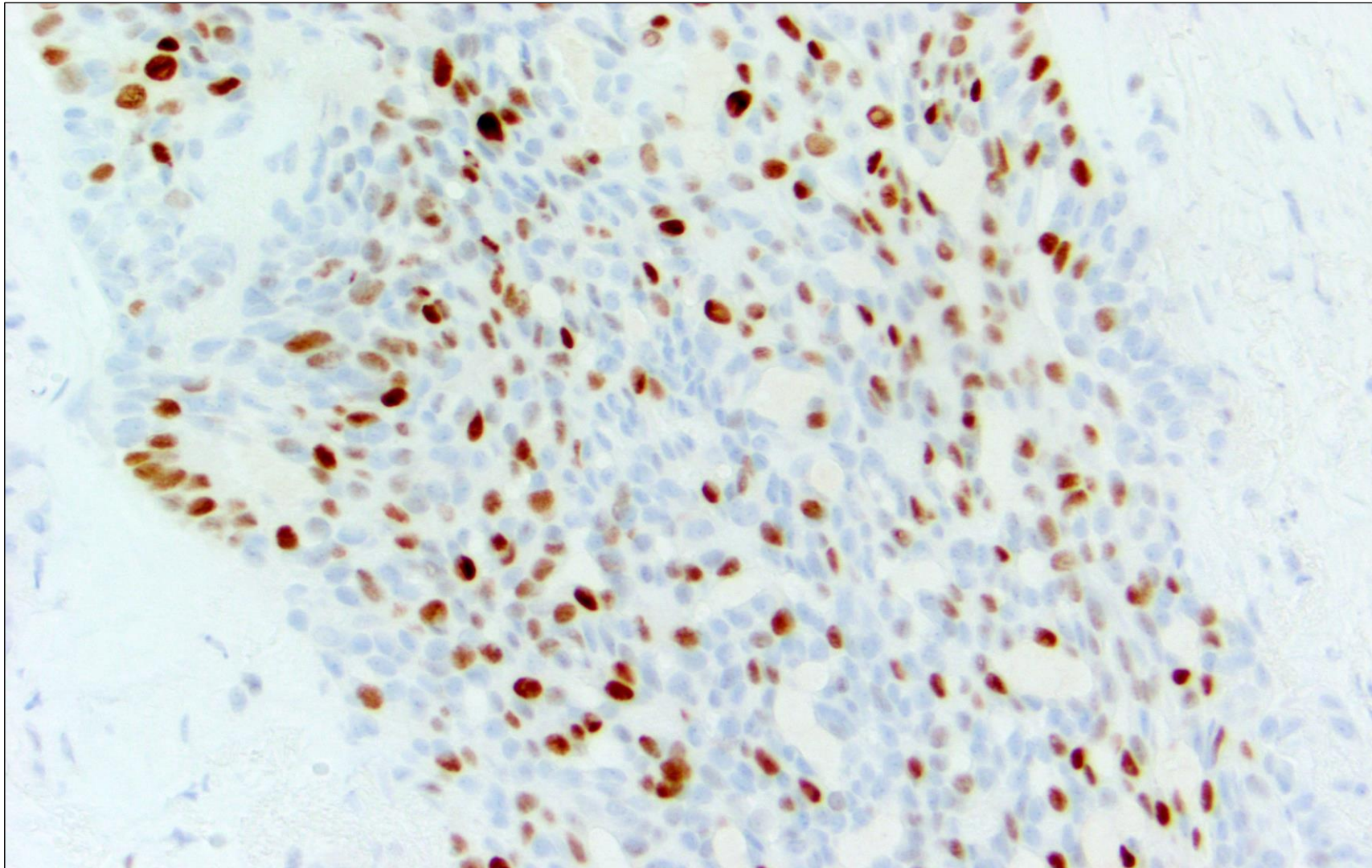
- Imagine the proliferation without the necrosis
- Are the features those of UDH or DCIS?

Involvement of benign sclerosing lesions can lead to misinterpretation as DCIS or IDC

- Is the stroma pink and fibrotic?
- Use MEC IHC if necessary, but interpret carefully
- Remember heterogeneous expression of ER is a useful safety check

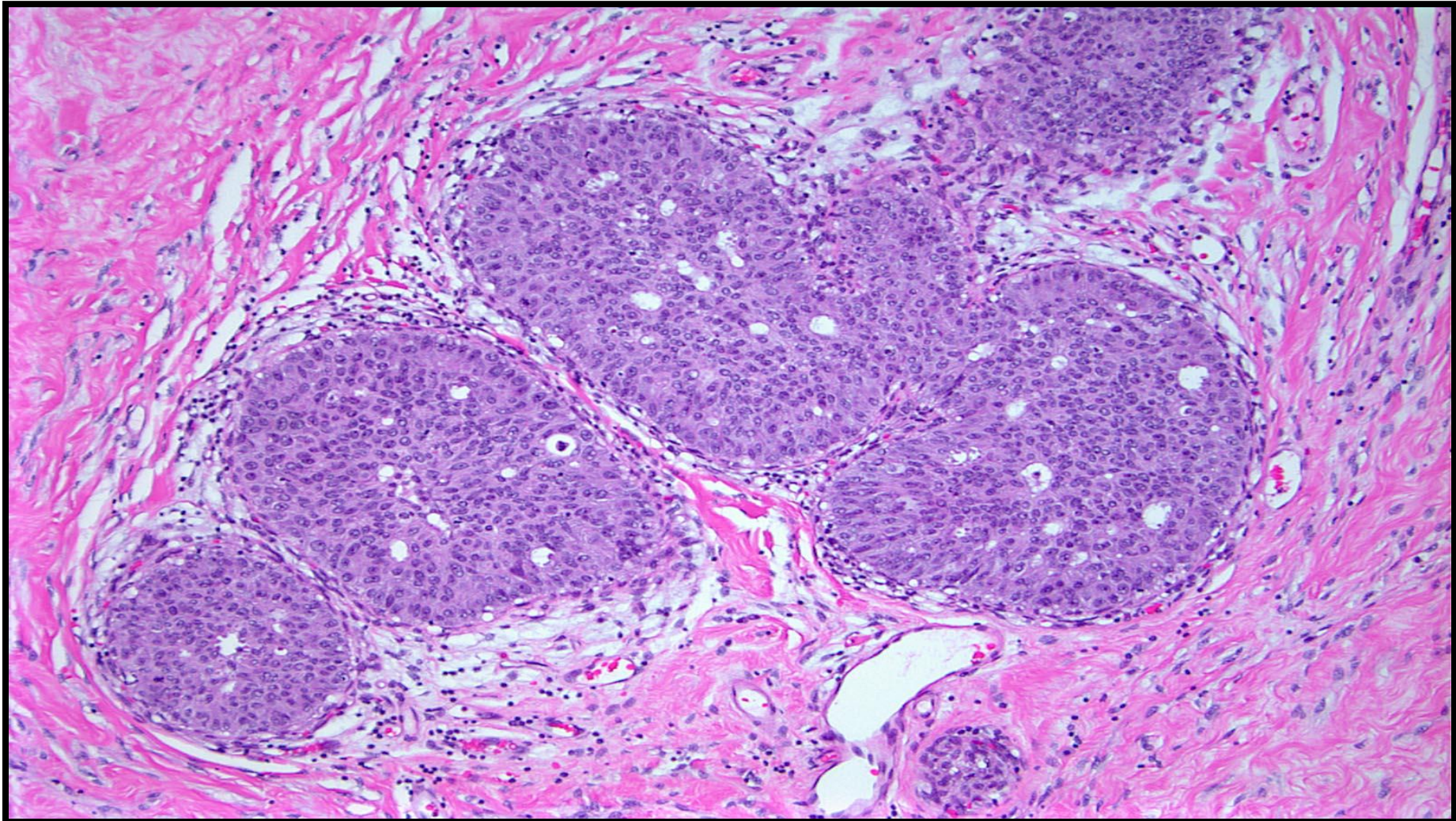


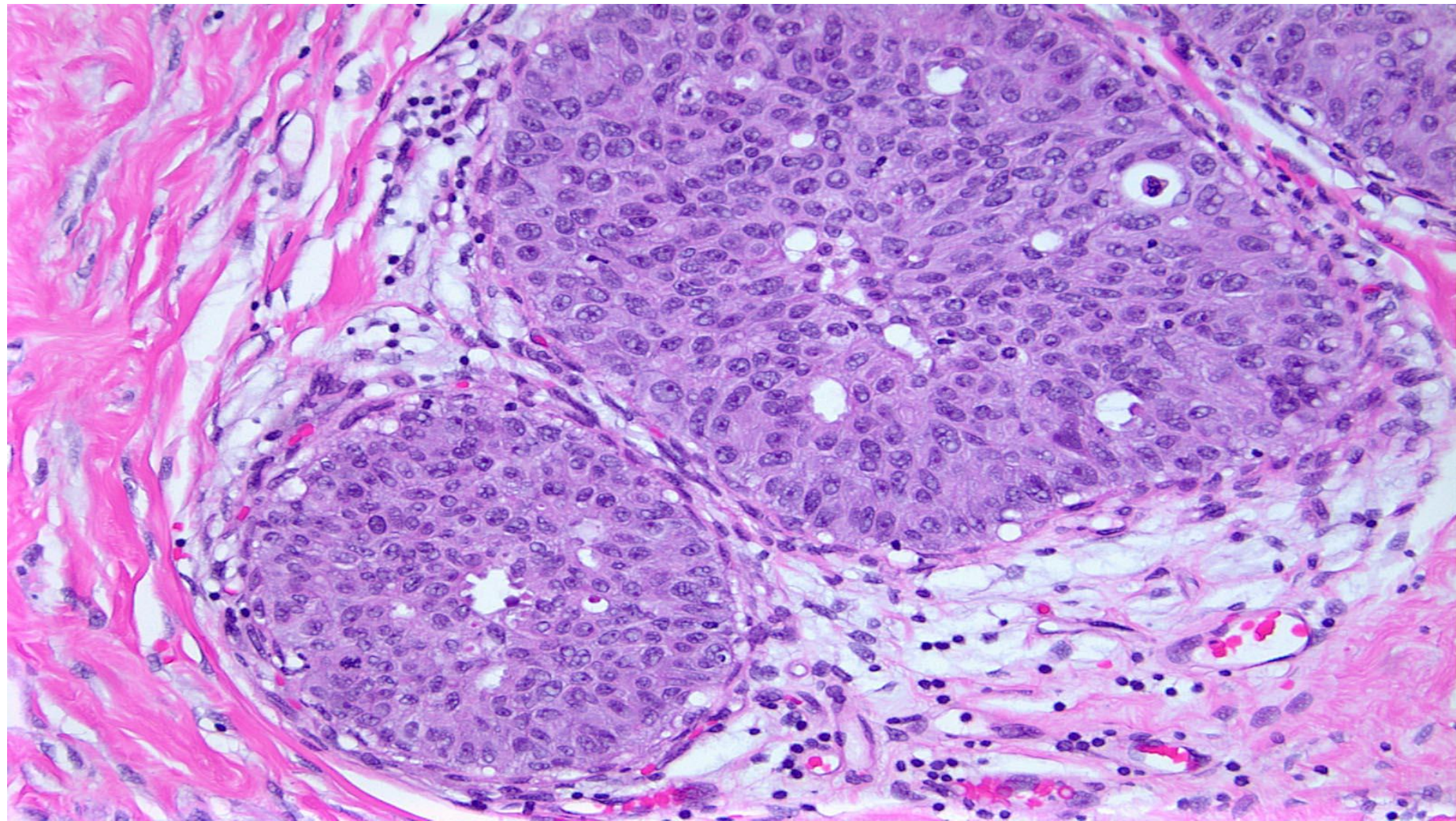




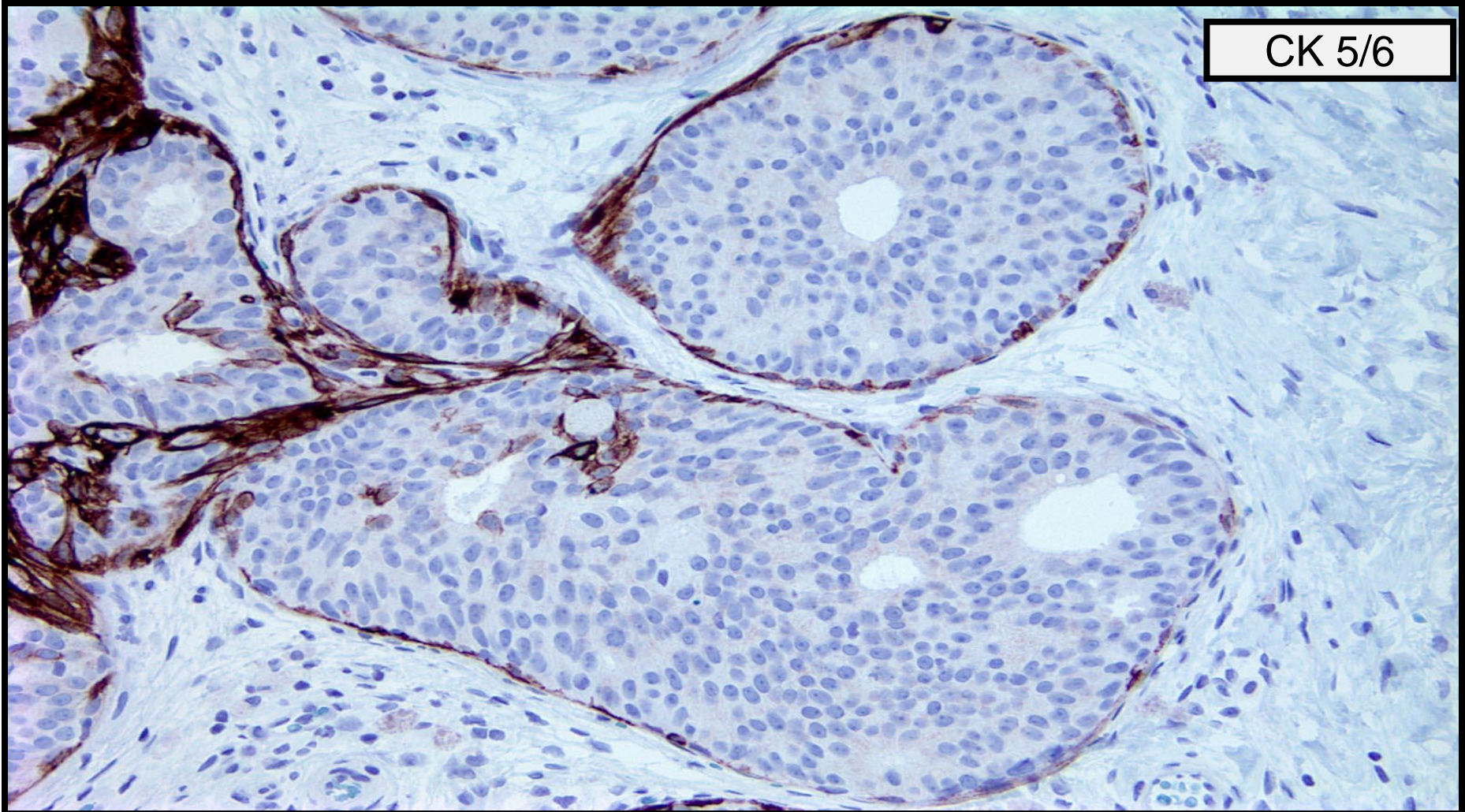
Other Differential Diagnostic Considerations

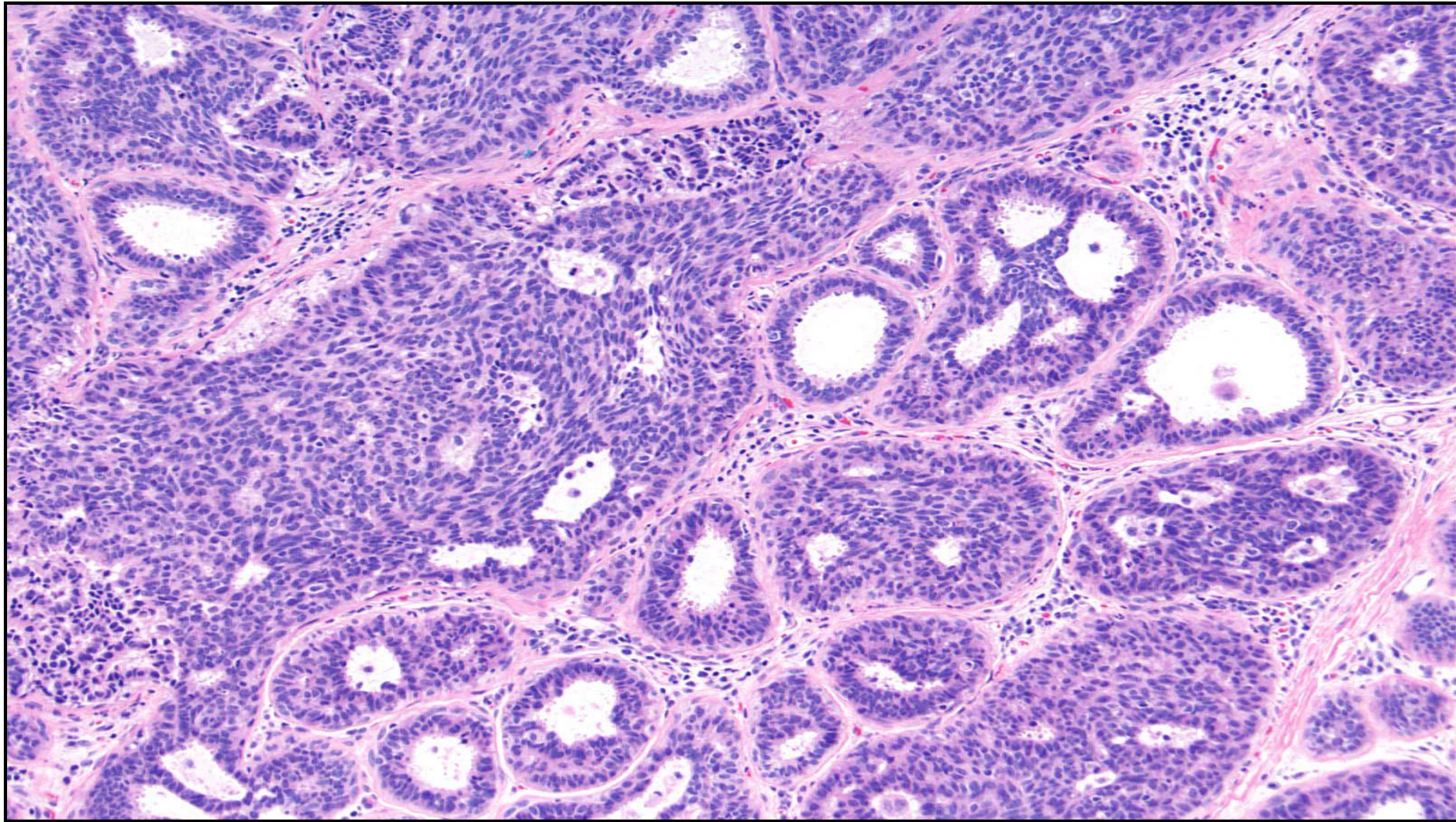
- Invasive carcinoma-when UDH involves a benign sclerosing lesion
- Solid papillary carcinoma-because of streaming of cells and more ovoid nuclei

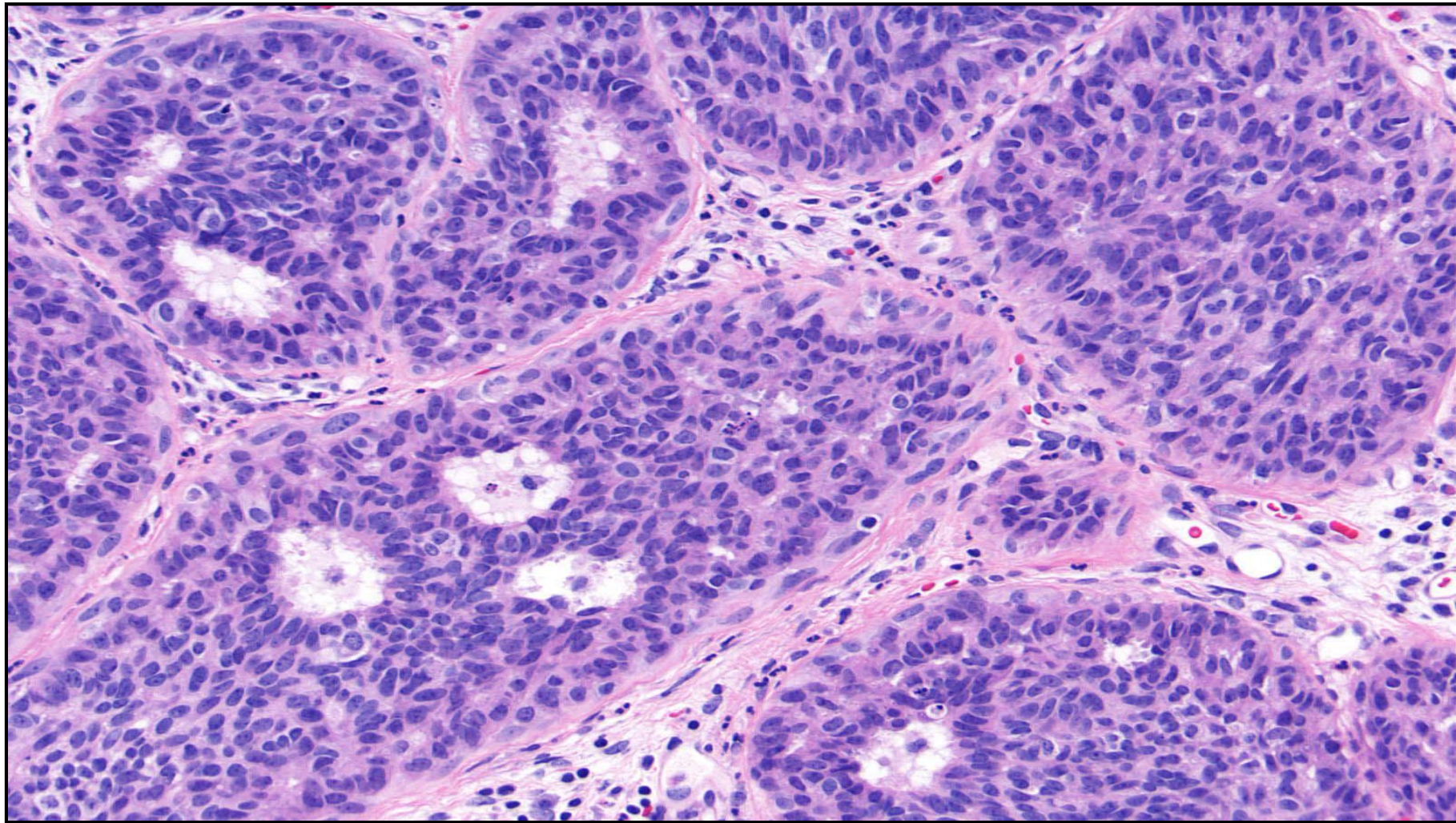


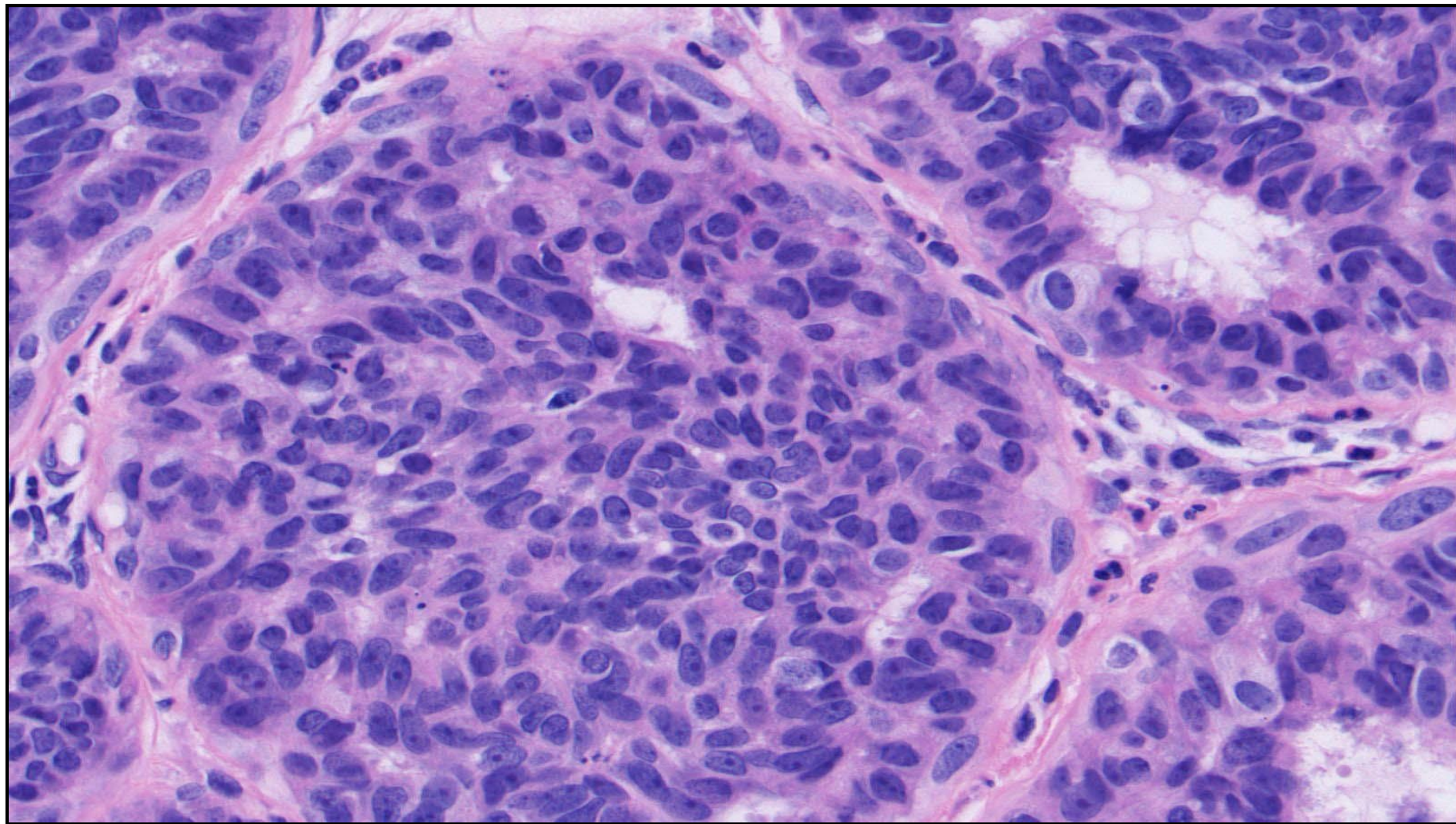


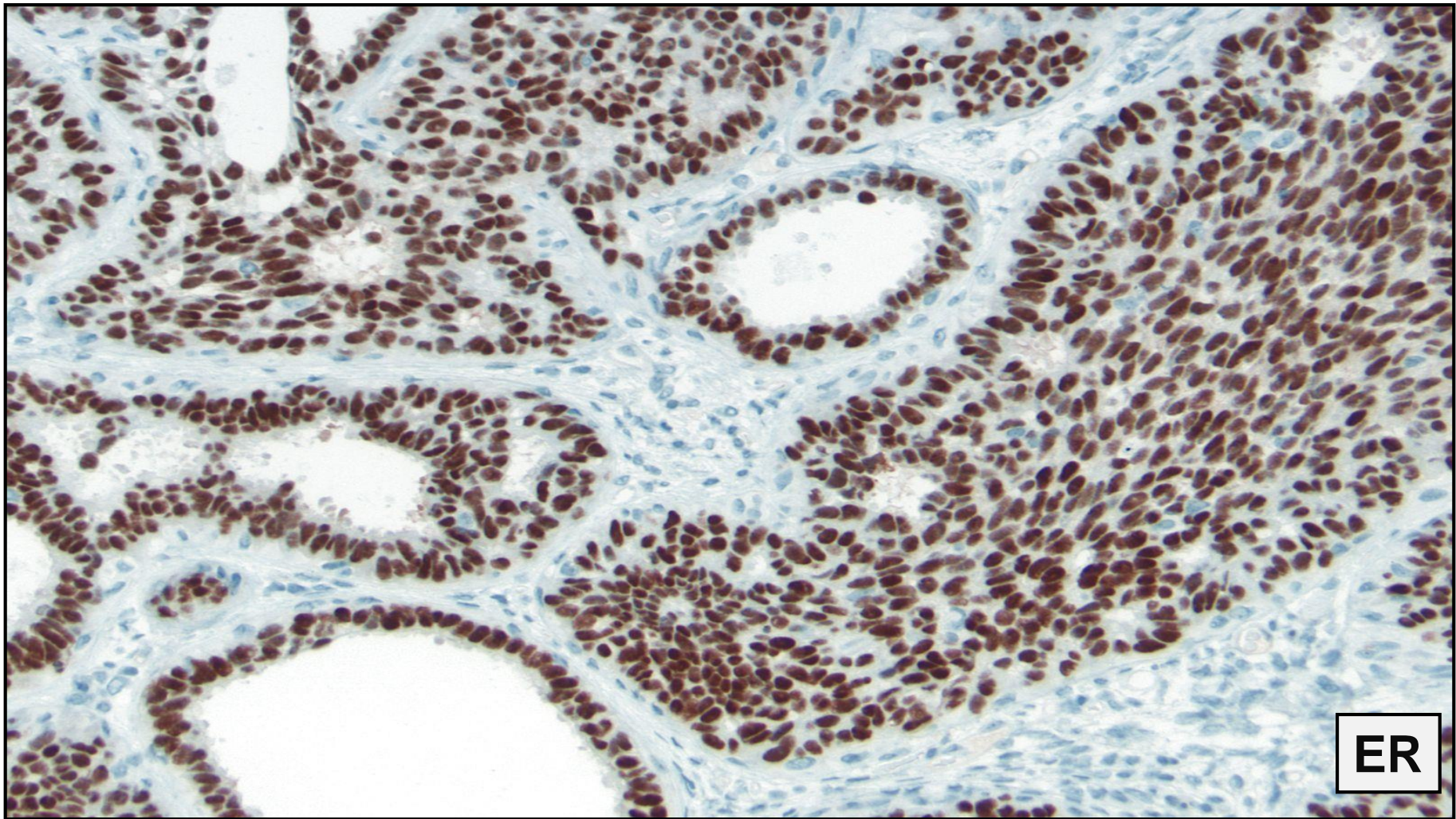
CK 5/6





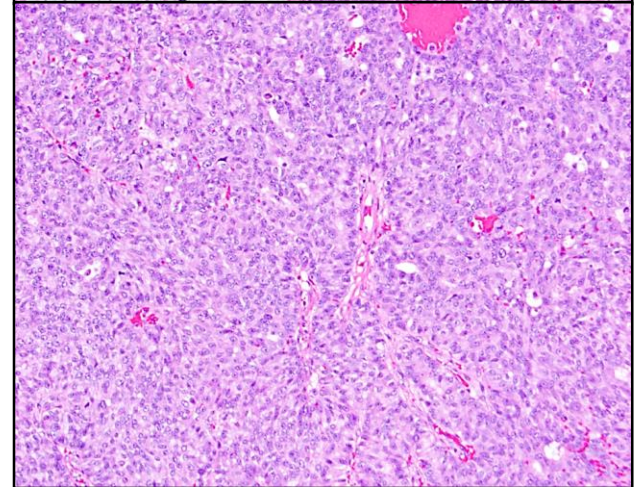
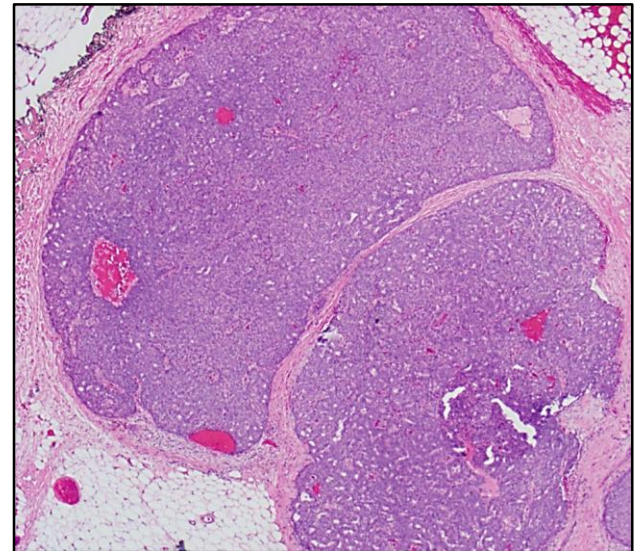
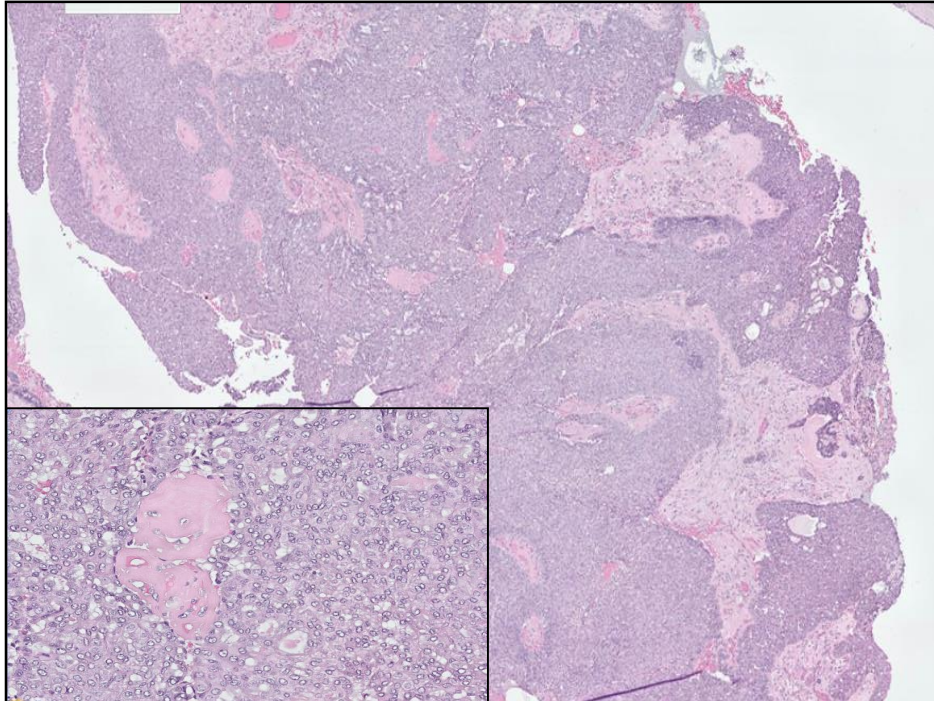






ER

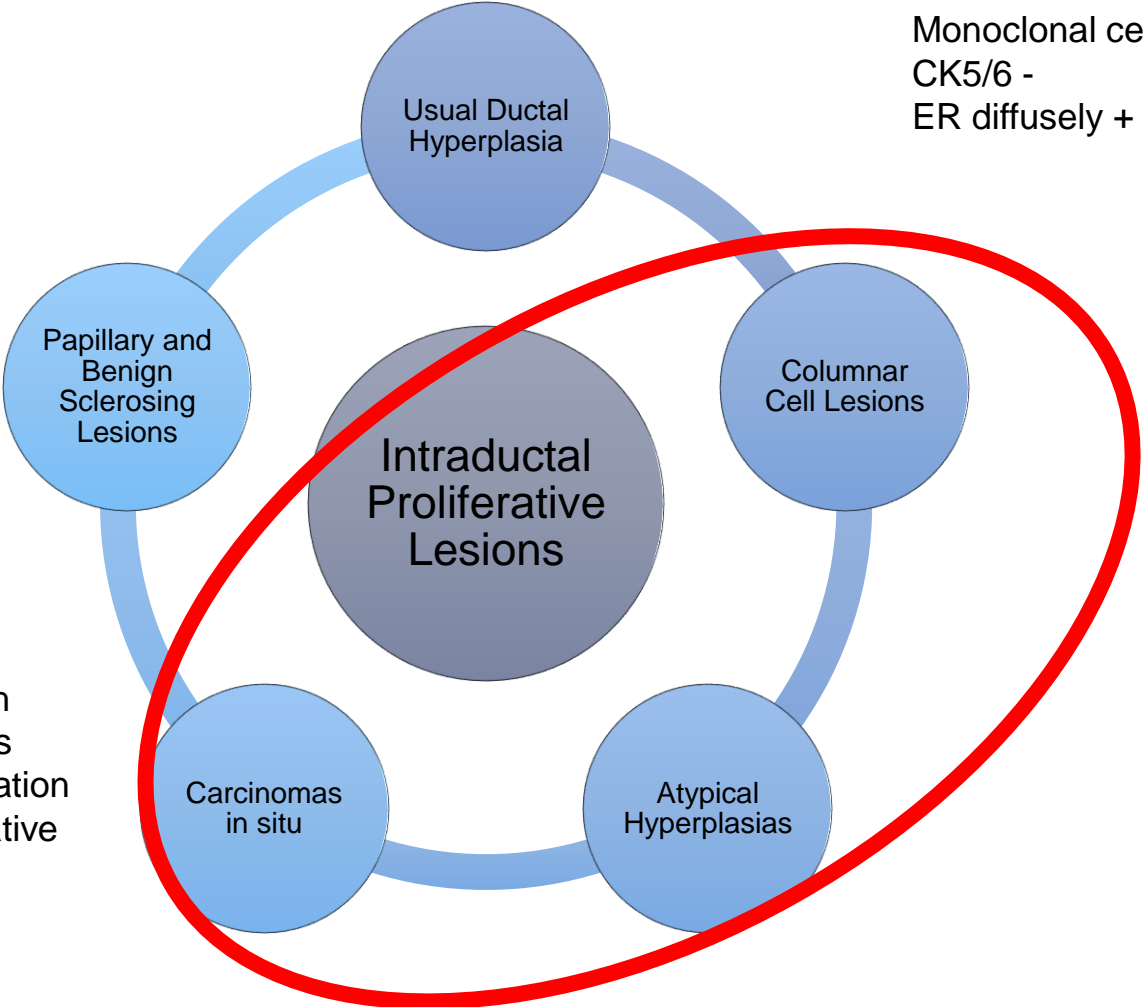
Papilloma with UDH vs. Solid Papillary Carcinoma



Management Impact

- Excision/Mastectomy/Bilateral mastectomy +/- SLN for DCIS/IDC
- No further management for UDH

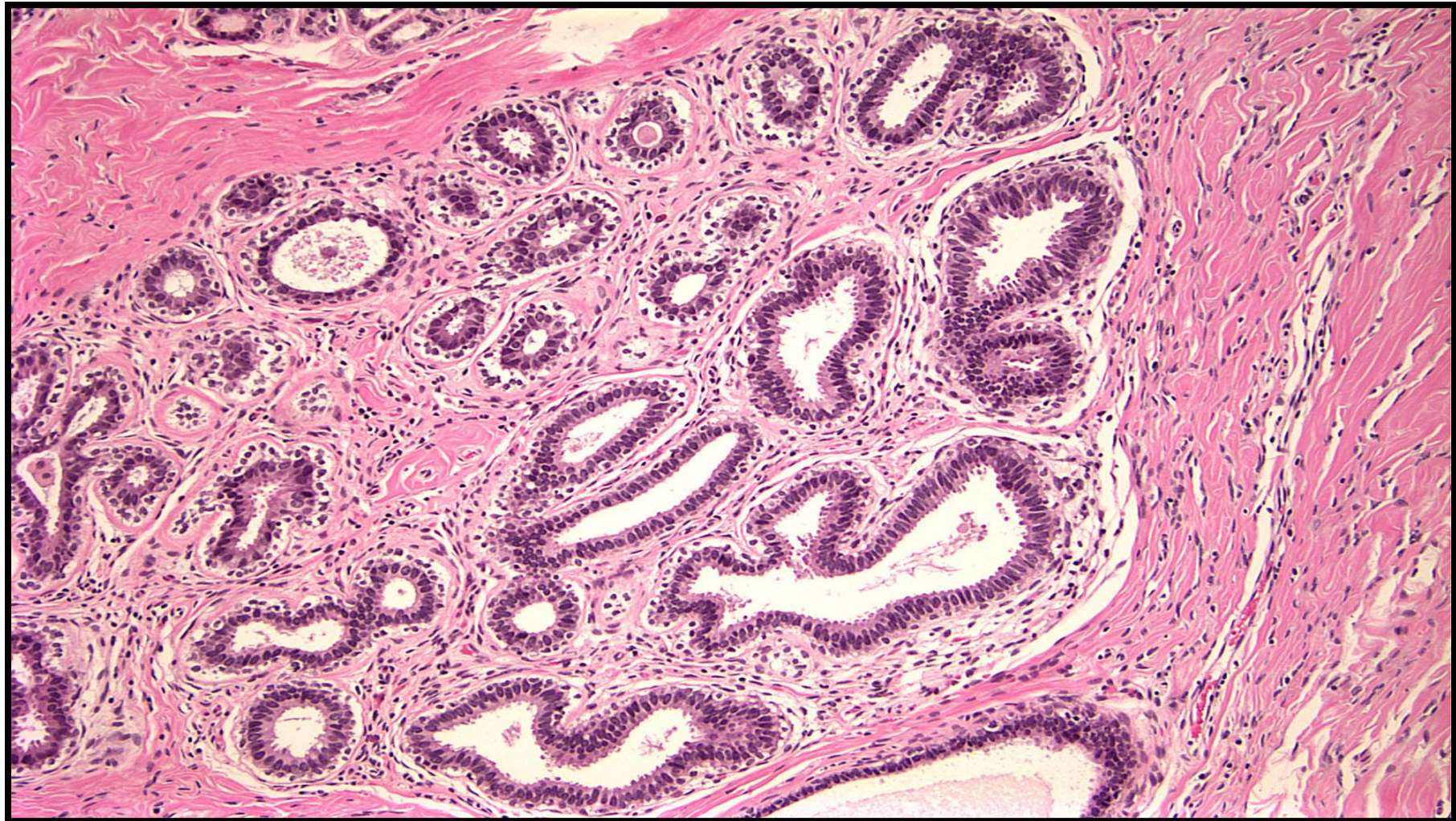
Monoclonal cell population
CK5/6 -
ER diffusely +

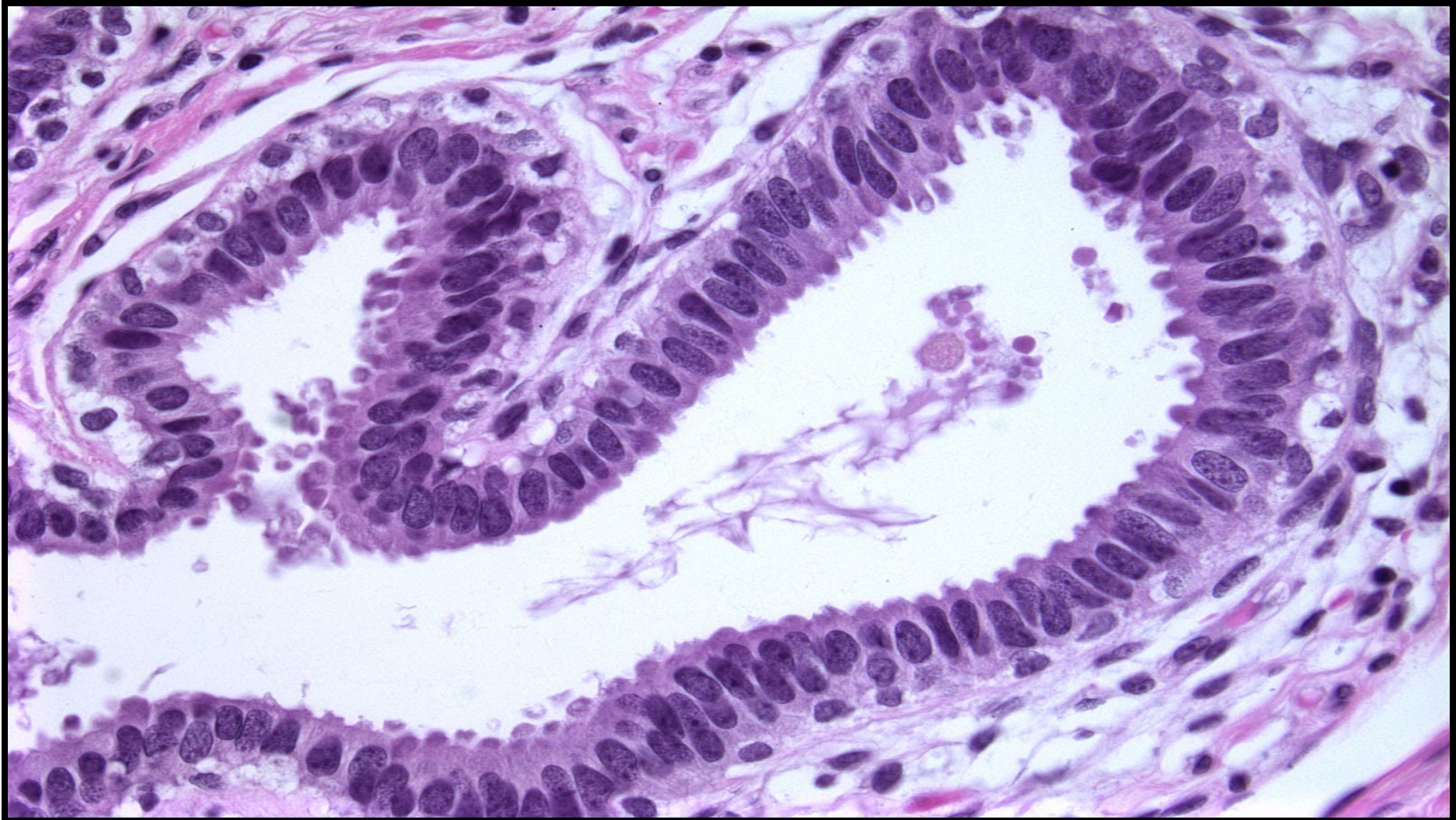


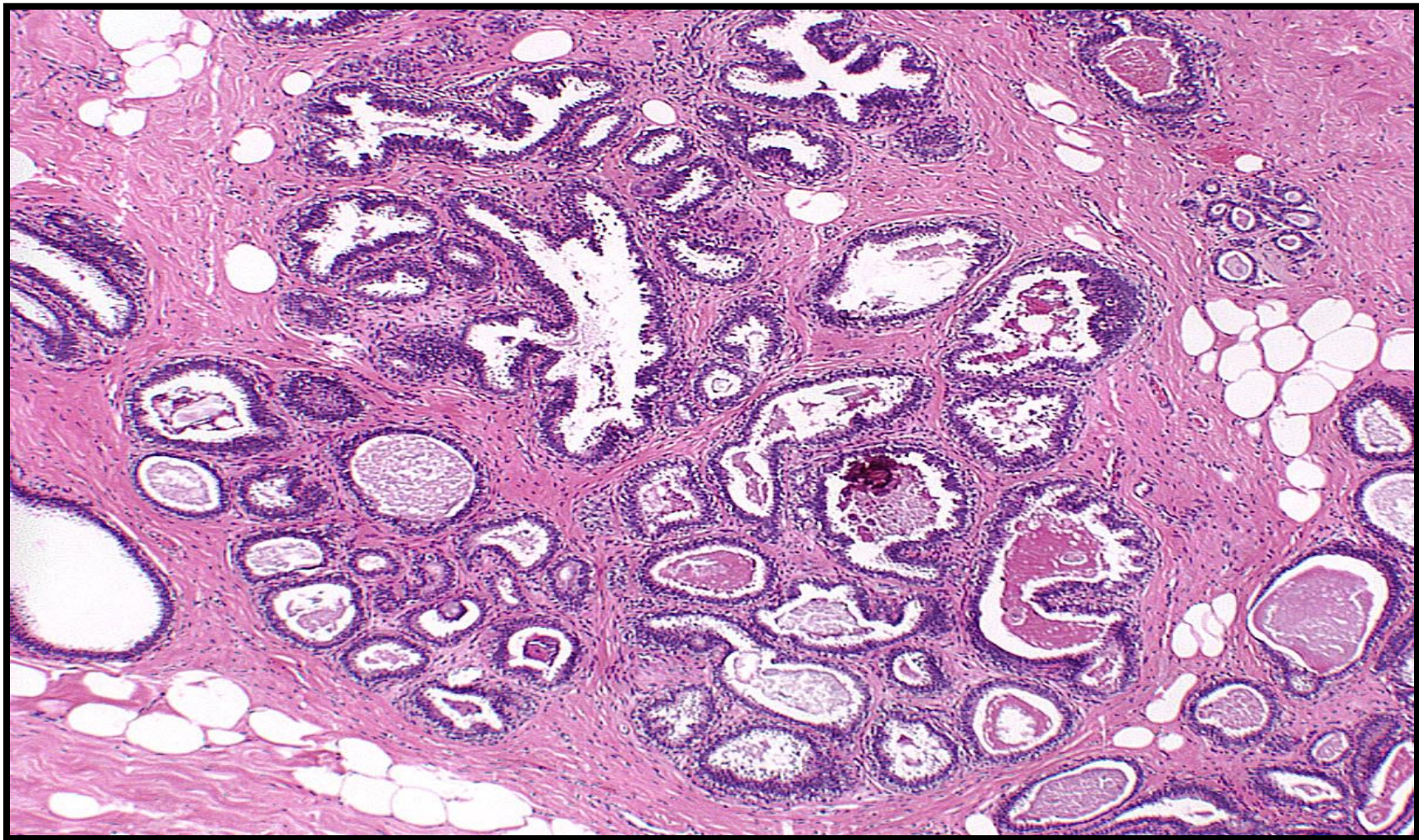
Exceptions include high grade DCIS and lesions with apocrine differentiation which may be ER negative

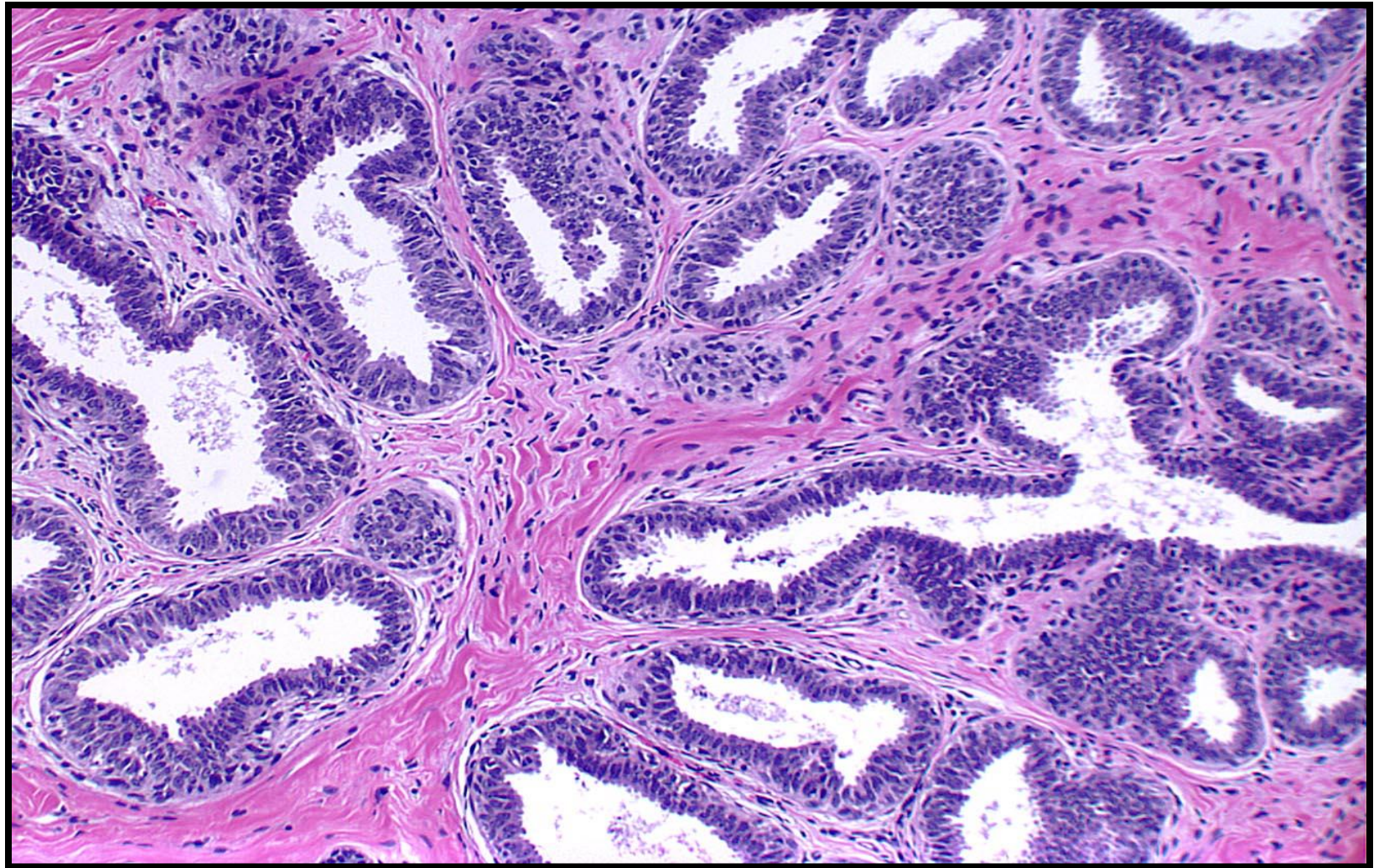
Columnar Cell Lesions without Atypia

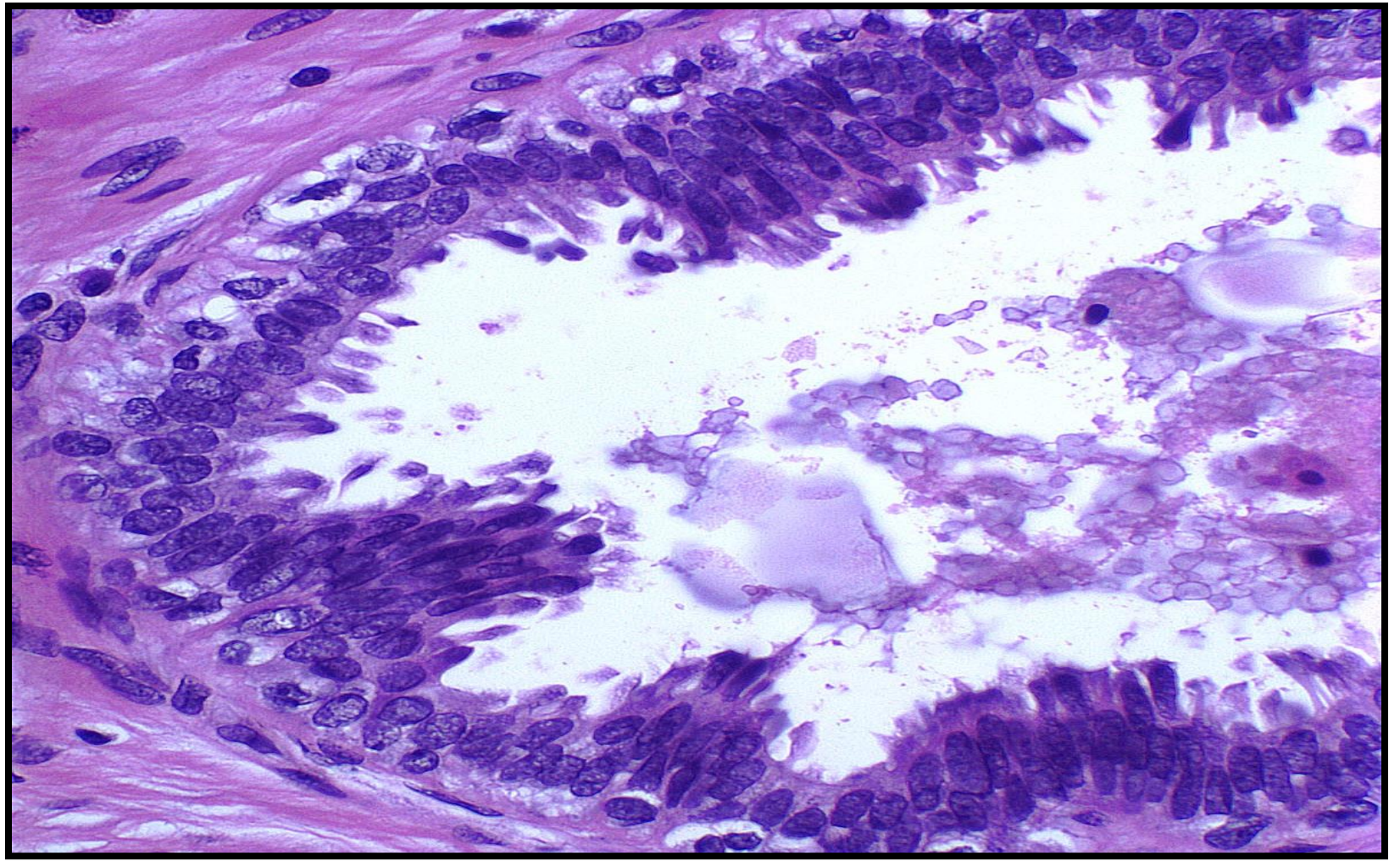
- Columnar cell change and columnar cell hyperplasia
- Variably distended acini of TDLUs
- Columnar epithelial cells
- Apical snouts
- Secretions and microcalcifications in lumens
- May see stratification of the lining in CCH











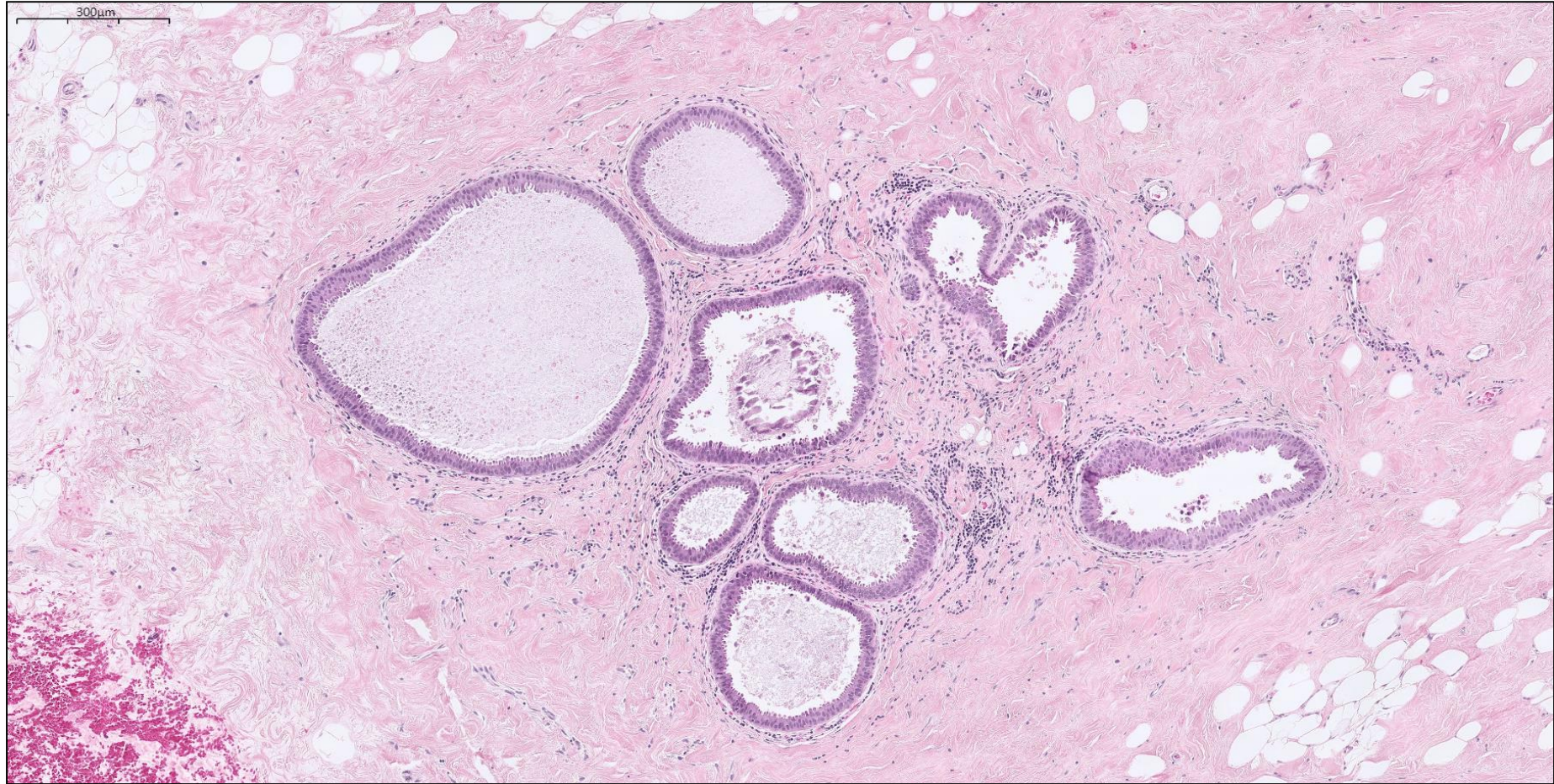
Flat Epithelial Atypia

- Variably distended acini of TDLUs
- Rigid acini
- Monotonous proliferation of cuboidal to columnar epithelial cells
- Apical snouts
- Secretions and microcalcifications in lumens

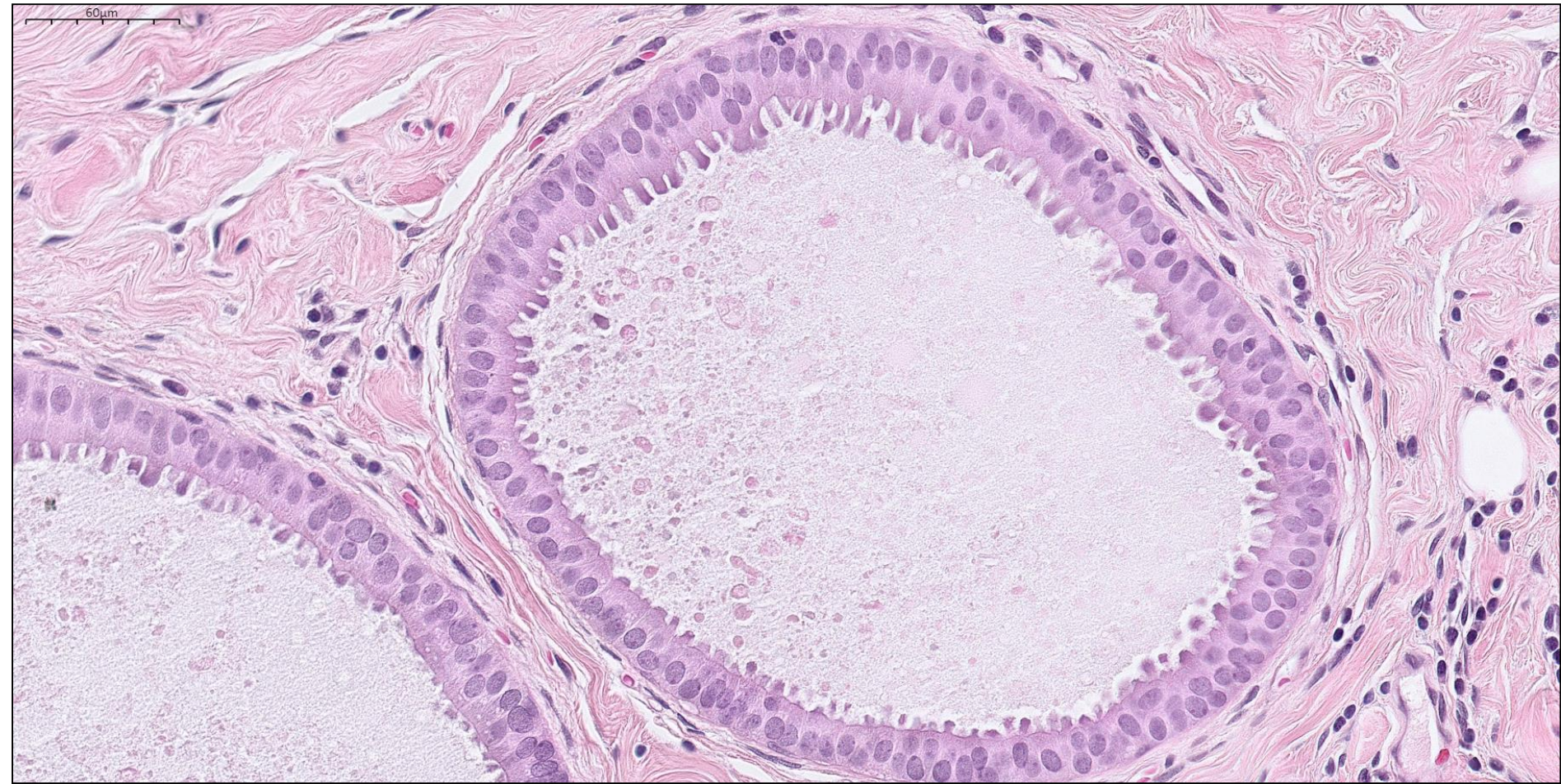
Flat Epithelial Atypia

- Low-grade cytologic atypia
- Nuclei usually round rather than elongated
- Loss of polarization
- Flat growth pattern

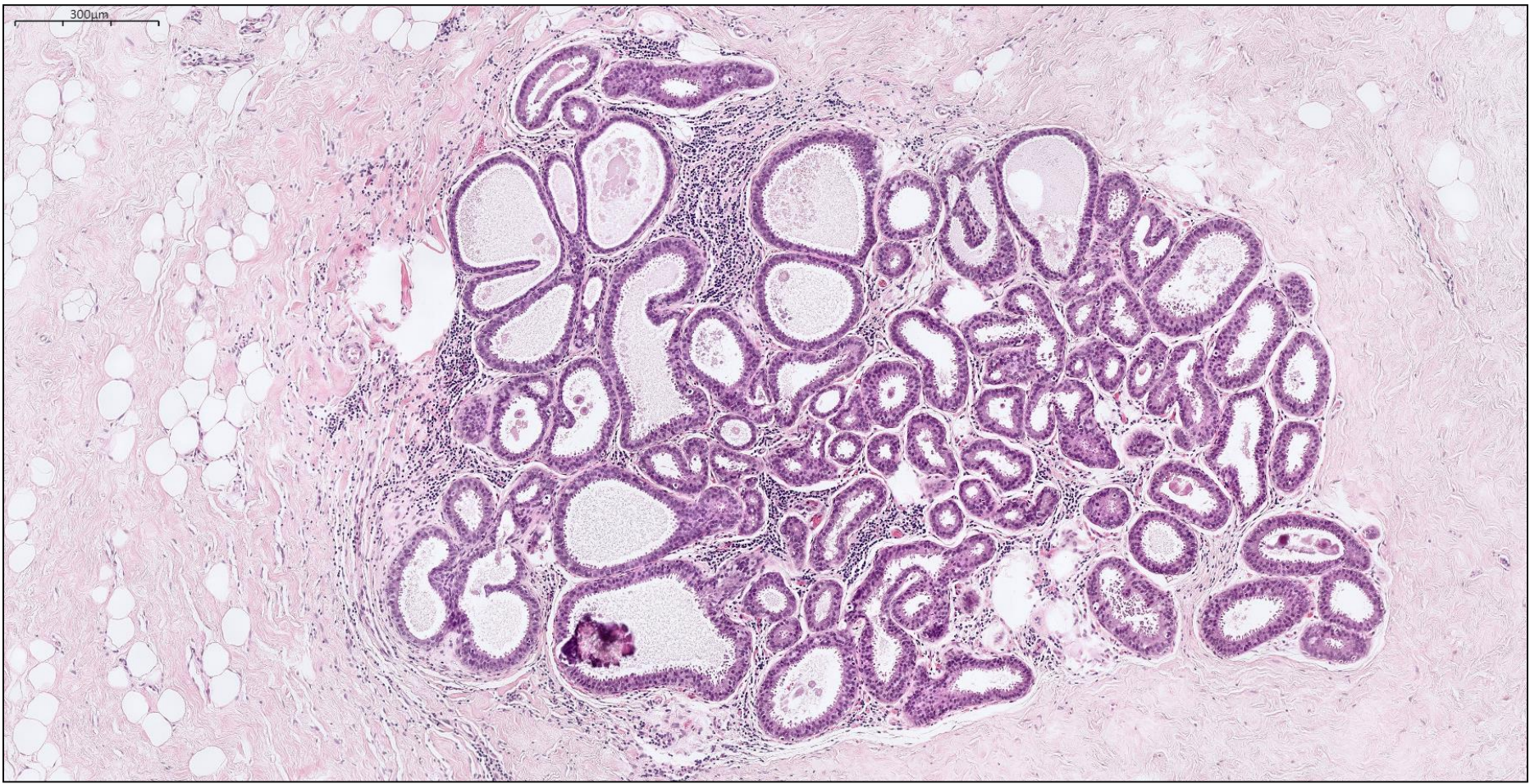
Features do not fulfill combined architectural and cytologic criteria for diagnosis of ADH or DCIS



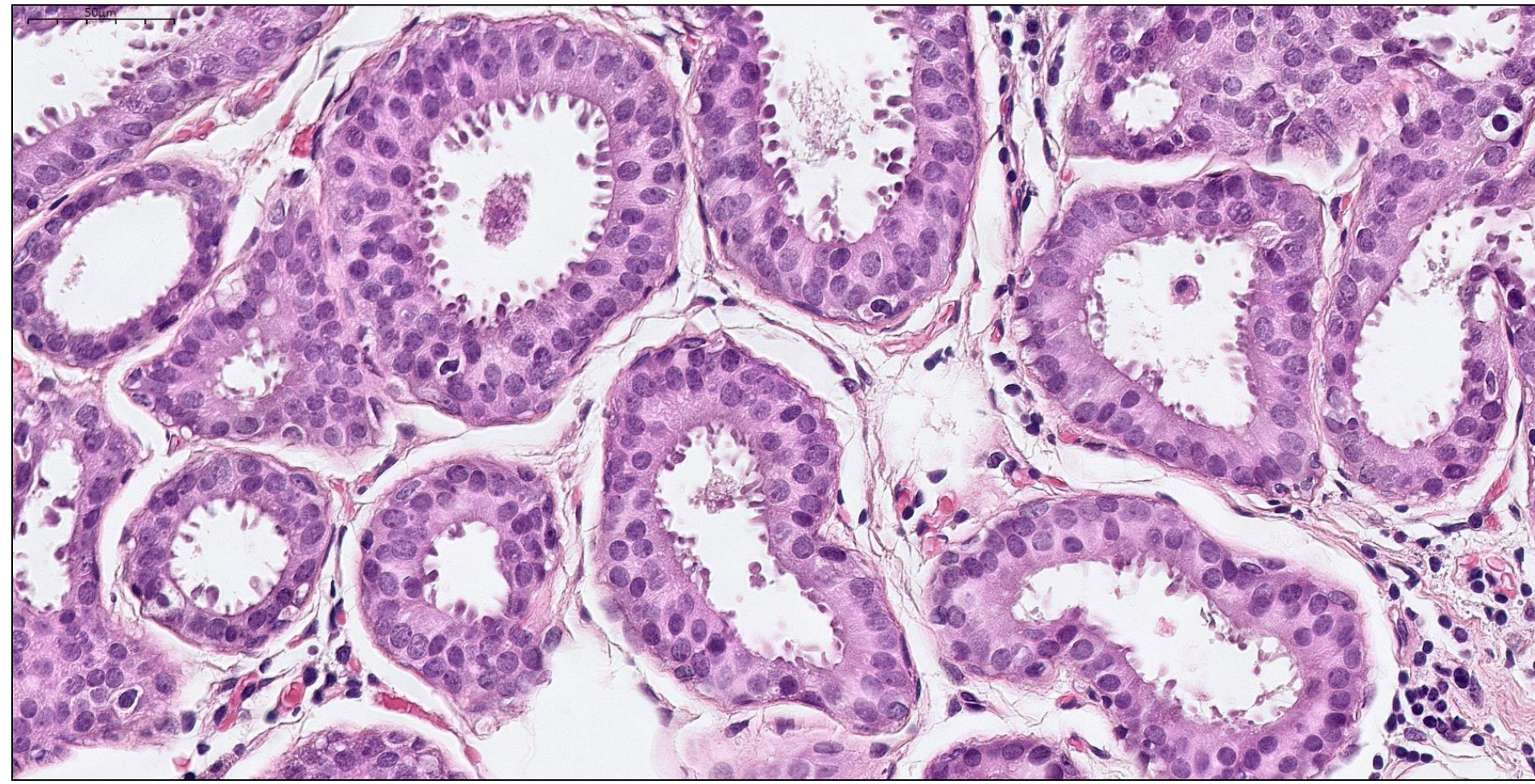
60µm



300µm



50µm



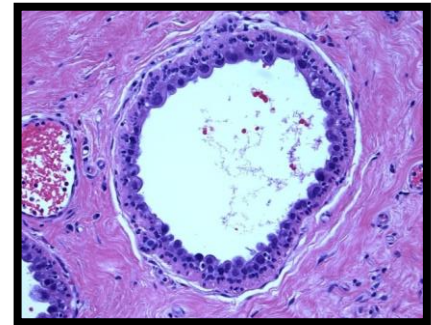
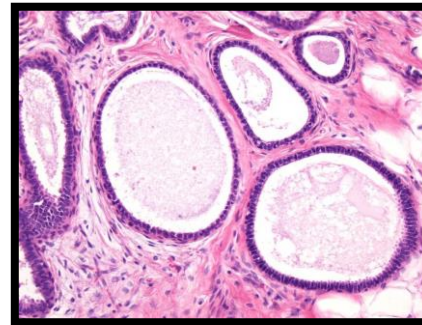
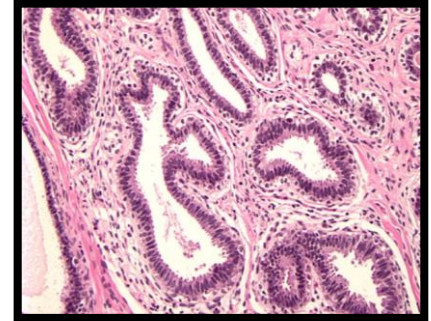
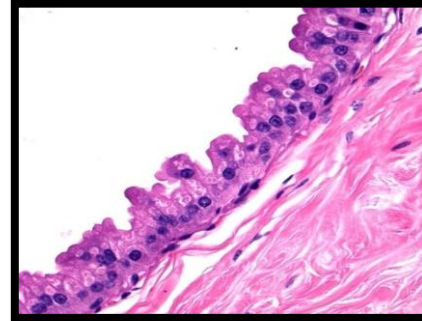
Differential Diagnosis of FEA

Microcysts

Apocrine metaplasia

Columnar cell change/hyperplasia

Clinging carcinoma (High grade DCIS)



Columnar Cell Lesions

- Increasingly seen in an era of mammographic screening due to the identification of microcalcifications
- Important to separate CCC/CCH from FEA on CNB, as some FEA excised

Columnar Cell Lesions

Biological Implications

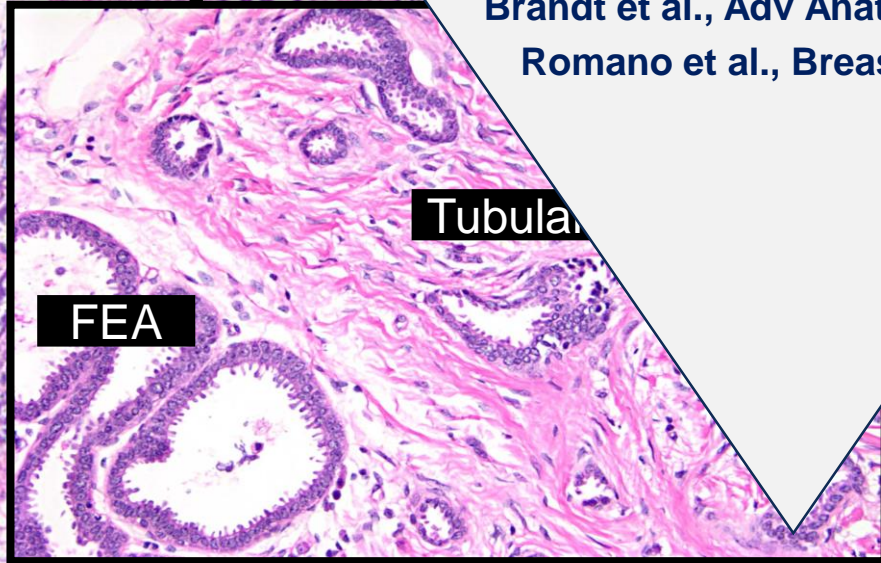
- Molecular evidence to suggest CCLs are a non-obligate precursor on the low grade breast neoplasia pathway
- Epidemiological evidence lacking
 - i.e. very low risk of progression to invasive carcinoma, and subsequent carcinomas are of all grades
- Should not be managed as a “high risk lesion”

Tubular ca

“ROSEN TRIAD”

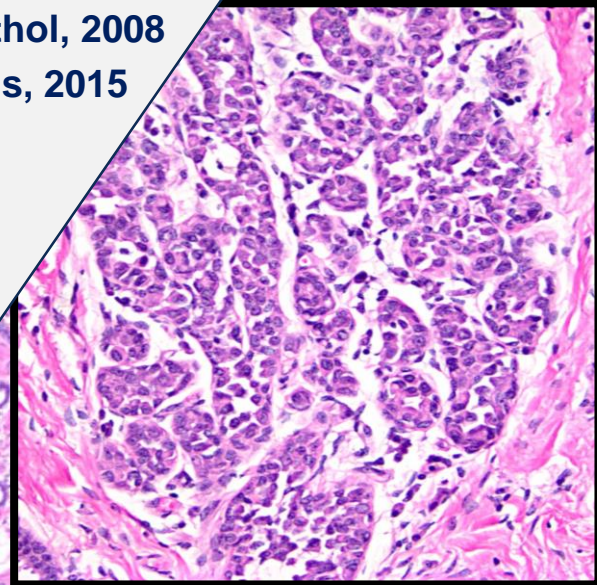
Rosen, Am J Surg Pathol, 1999
Brandt et al., Adv Anat Pathol, 2008
Romano et al., Breast Dis, 2015

FEA



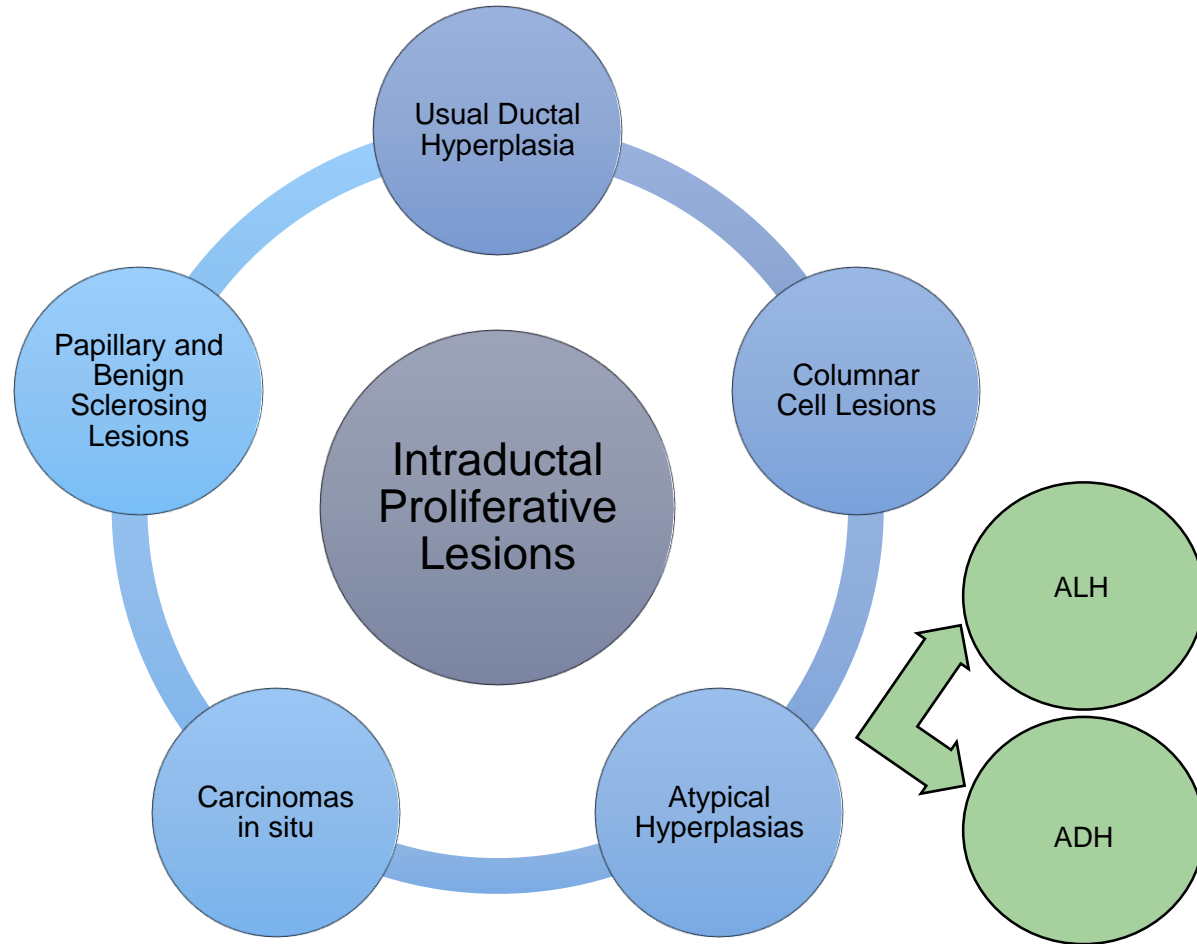
Tubular ca

FEA



Columnar Cell Lesions

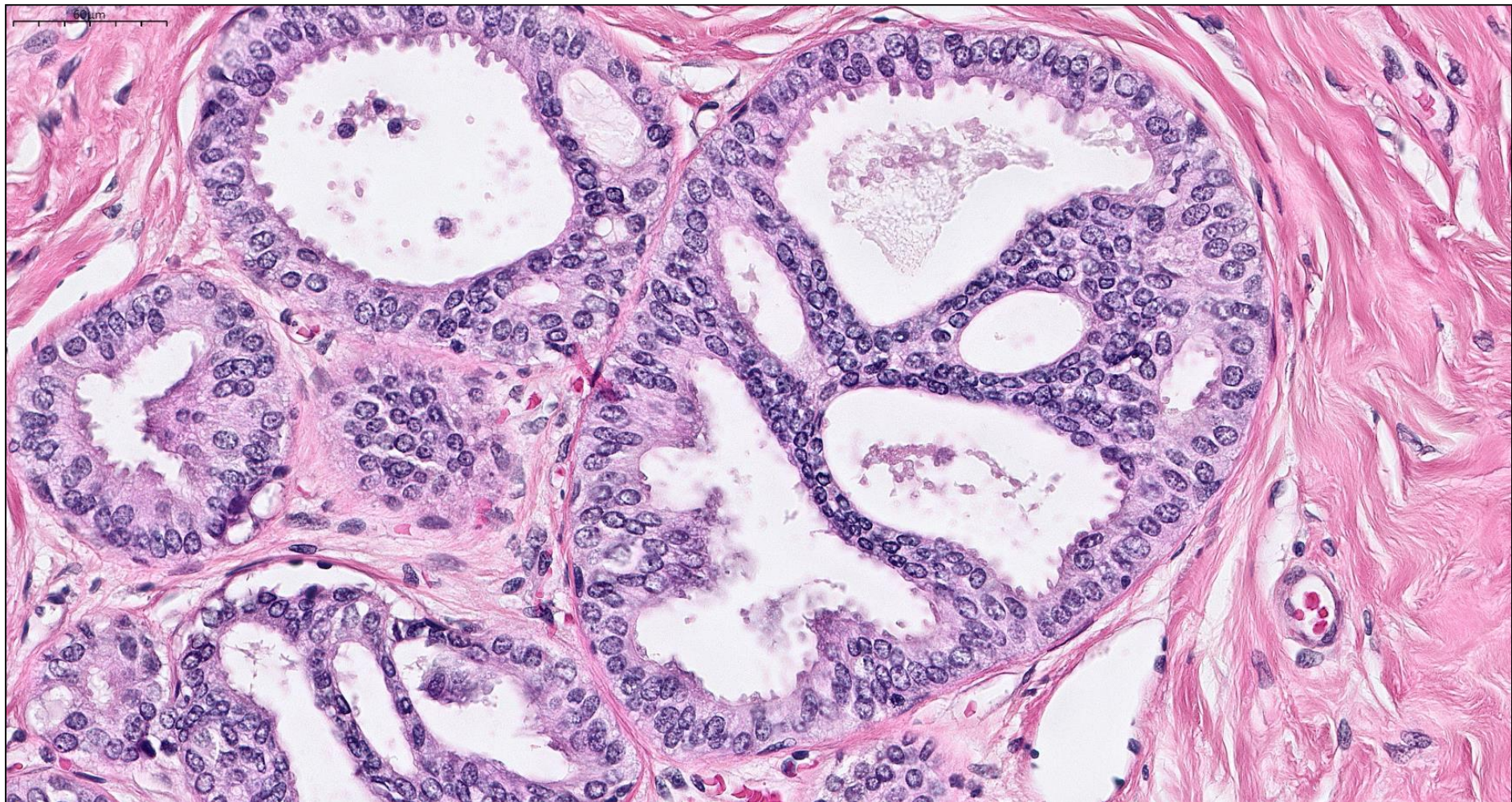
- Not usually a diagnostic dilemma
- Be careful not to overcall FEA
- Usually recognizable at low power
- Important to look for other associated/more significant lesions

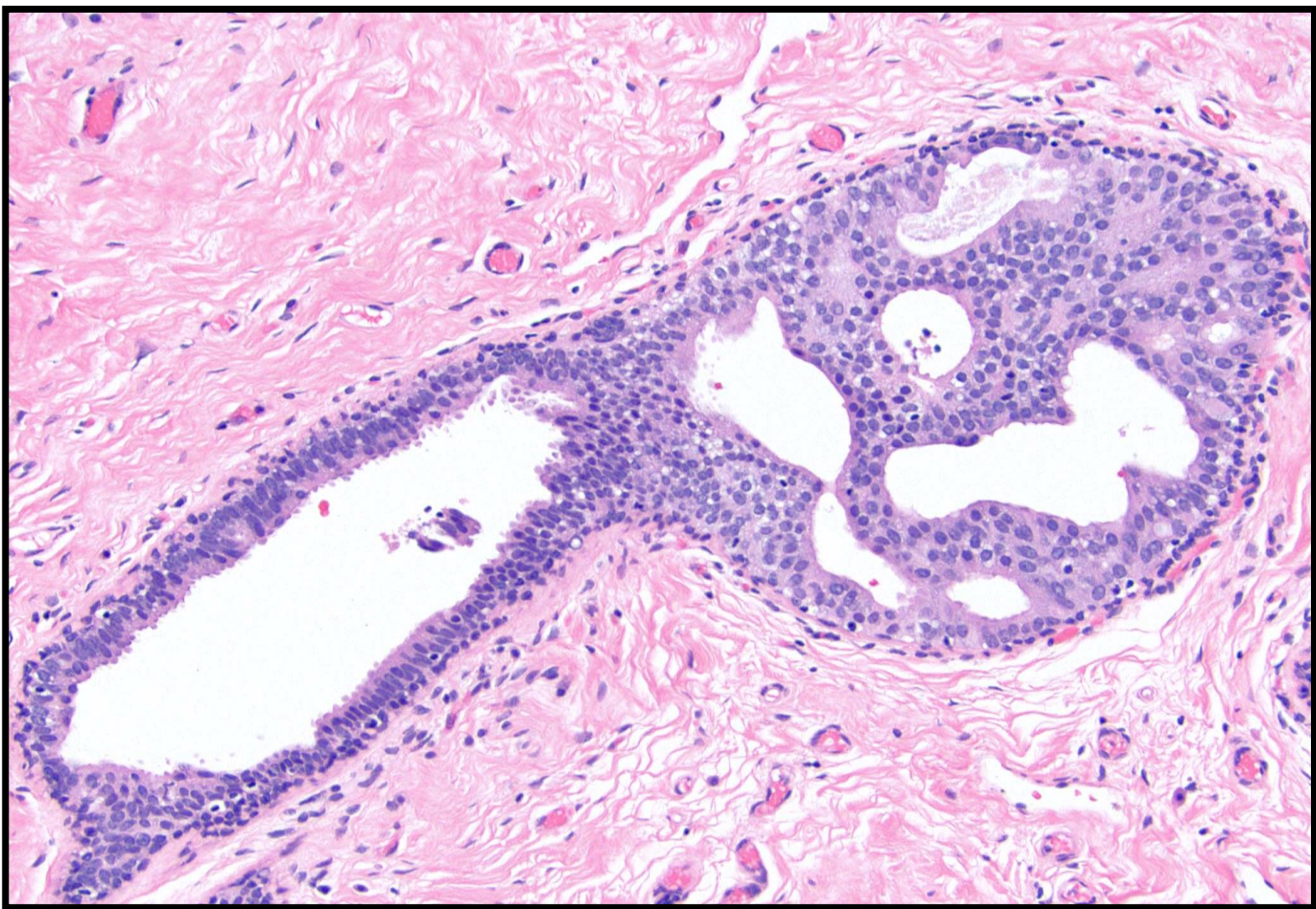


Atypical Ductal Hyperplasia

Key Features of ADH

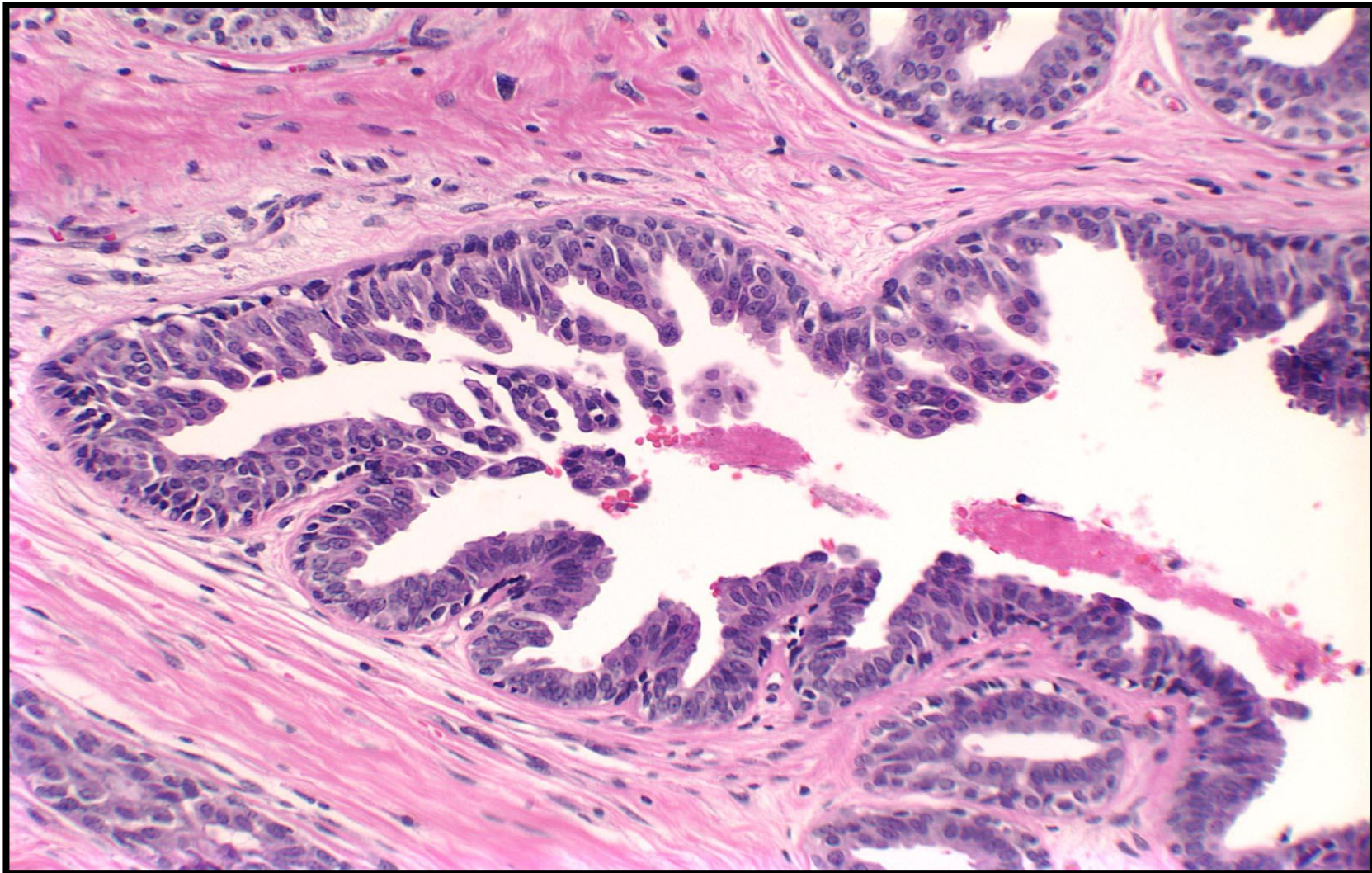
Cytologic Features	Atypical cell population, similar to that seen in LG DCIS; small uniform cells with well-defined borders and generally rounded, evenly spaced, nuclei
<hr/>	
Architectural Features	In association with atypical cell population, rigid bridges and arcades of uniform thickness, micropapillations with bulbous tips, cribriform pattern with polarization of cells around lumens, solid pattern
<hr/>	
Size/Extent	Partial involvement of multiple spaces; complete involvement of <2 spaces, or ≤ 2 mm in extent



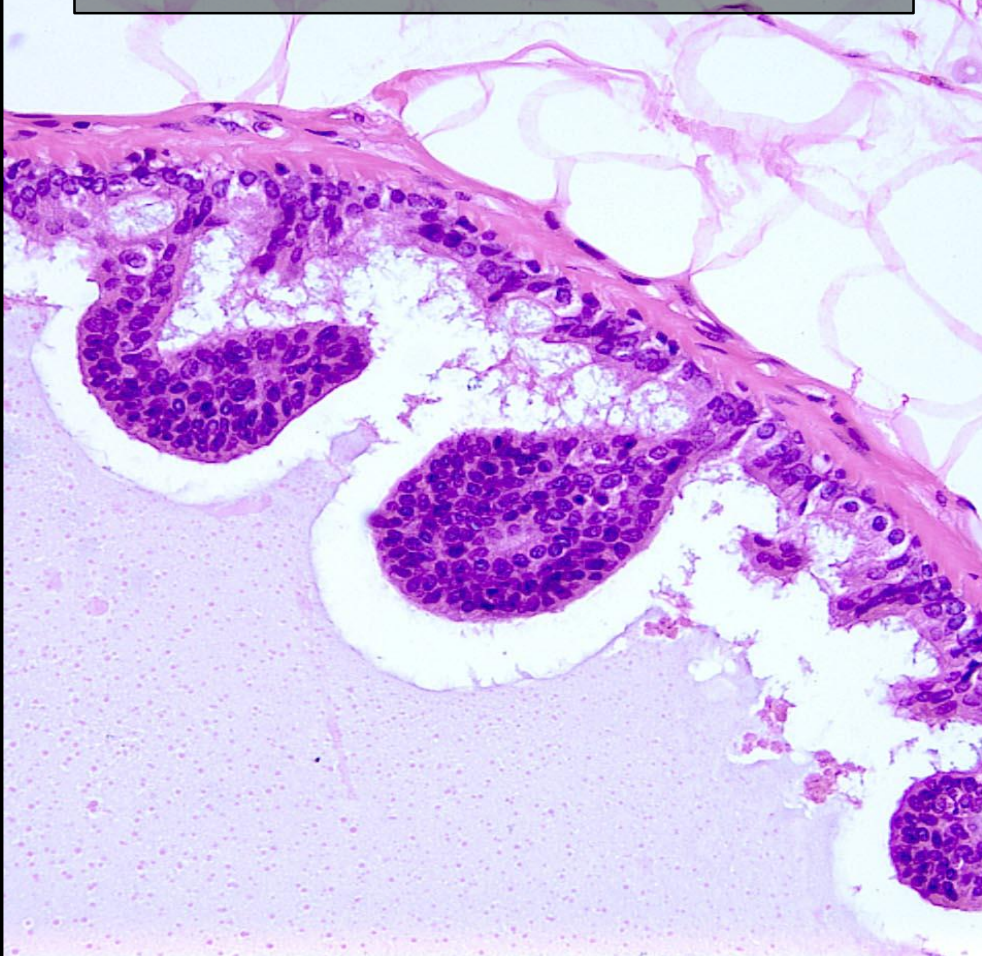


Differential Diagnosis of ADH

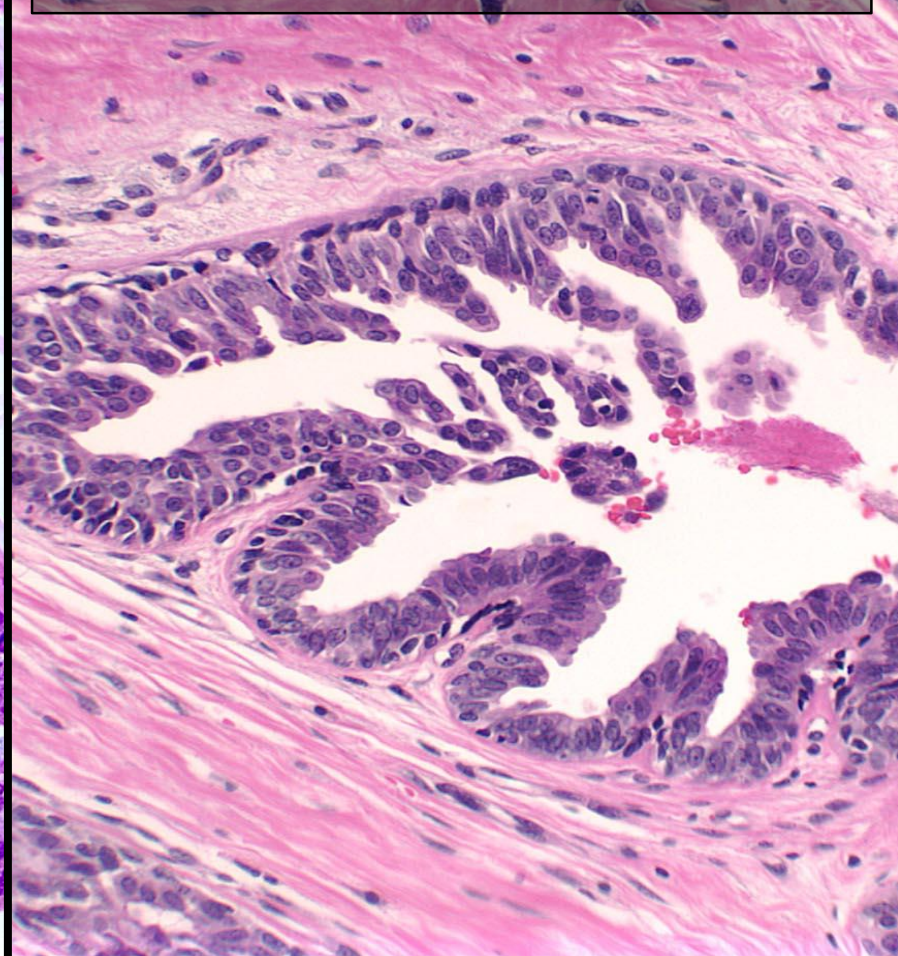
- LG DCIS
- Usual ductal hyperplasia
 - Micropapillary pattern (gynecomastoid)
- Collagenous spherulosis

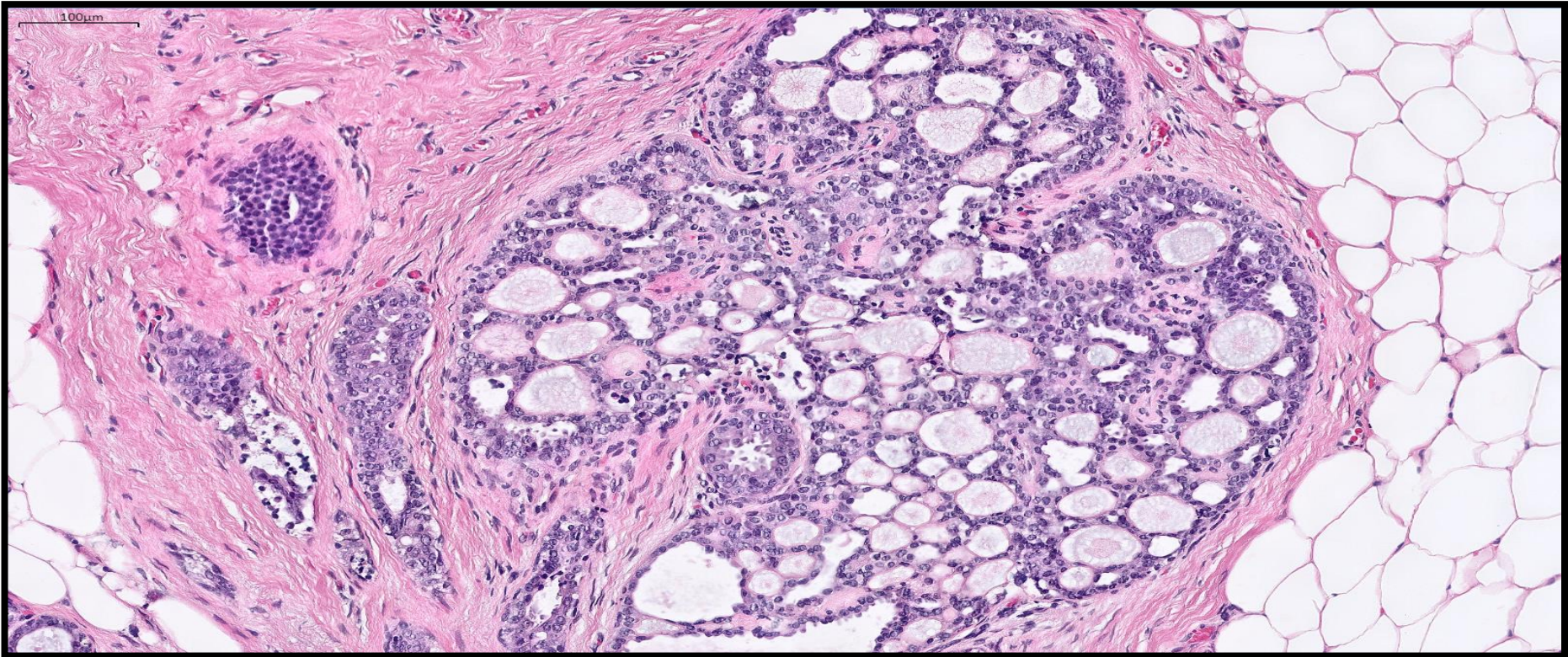


Micropapillary ADH

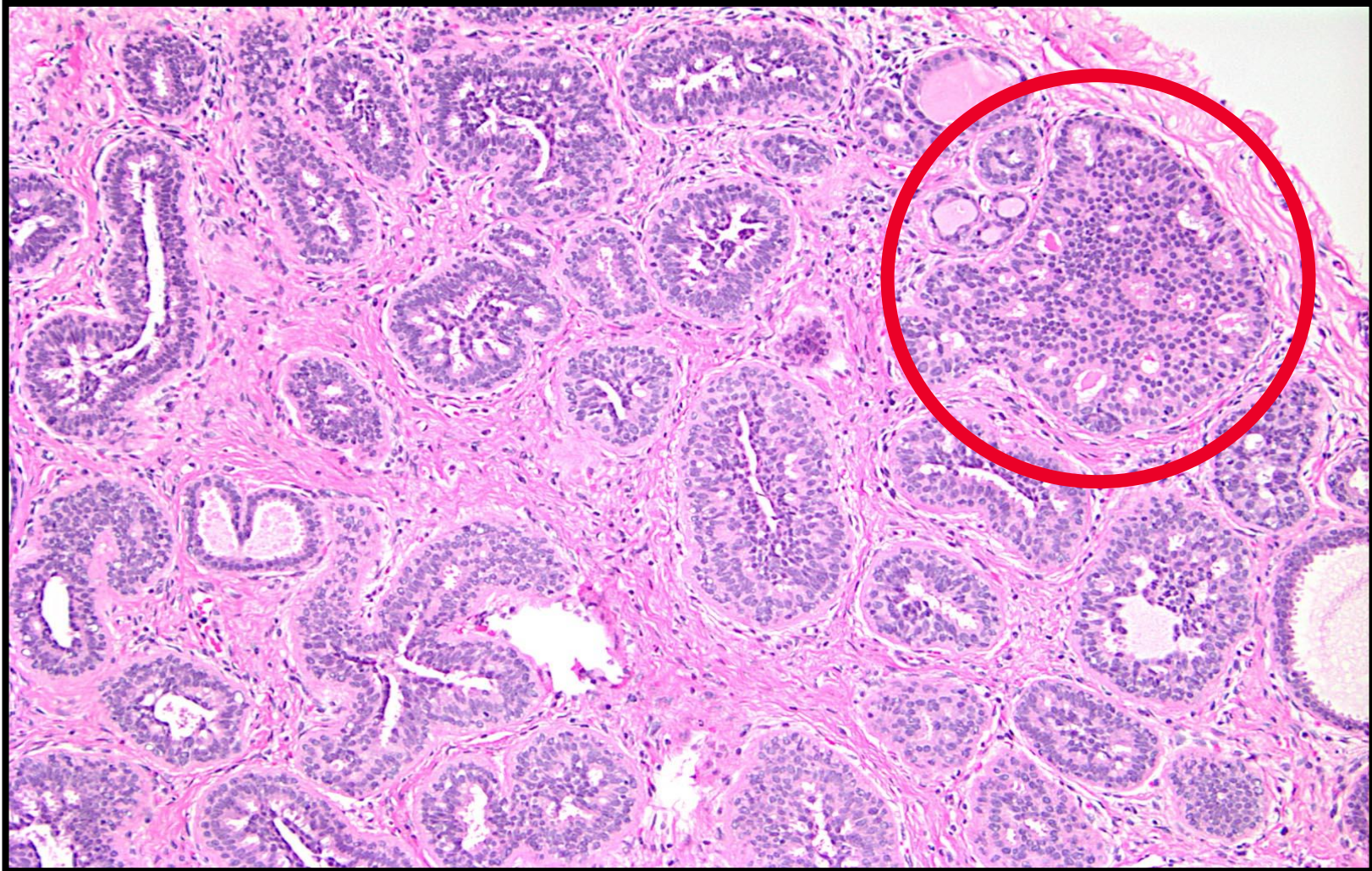


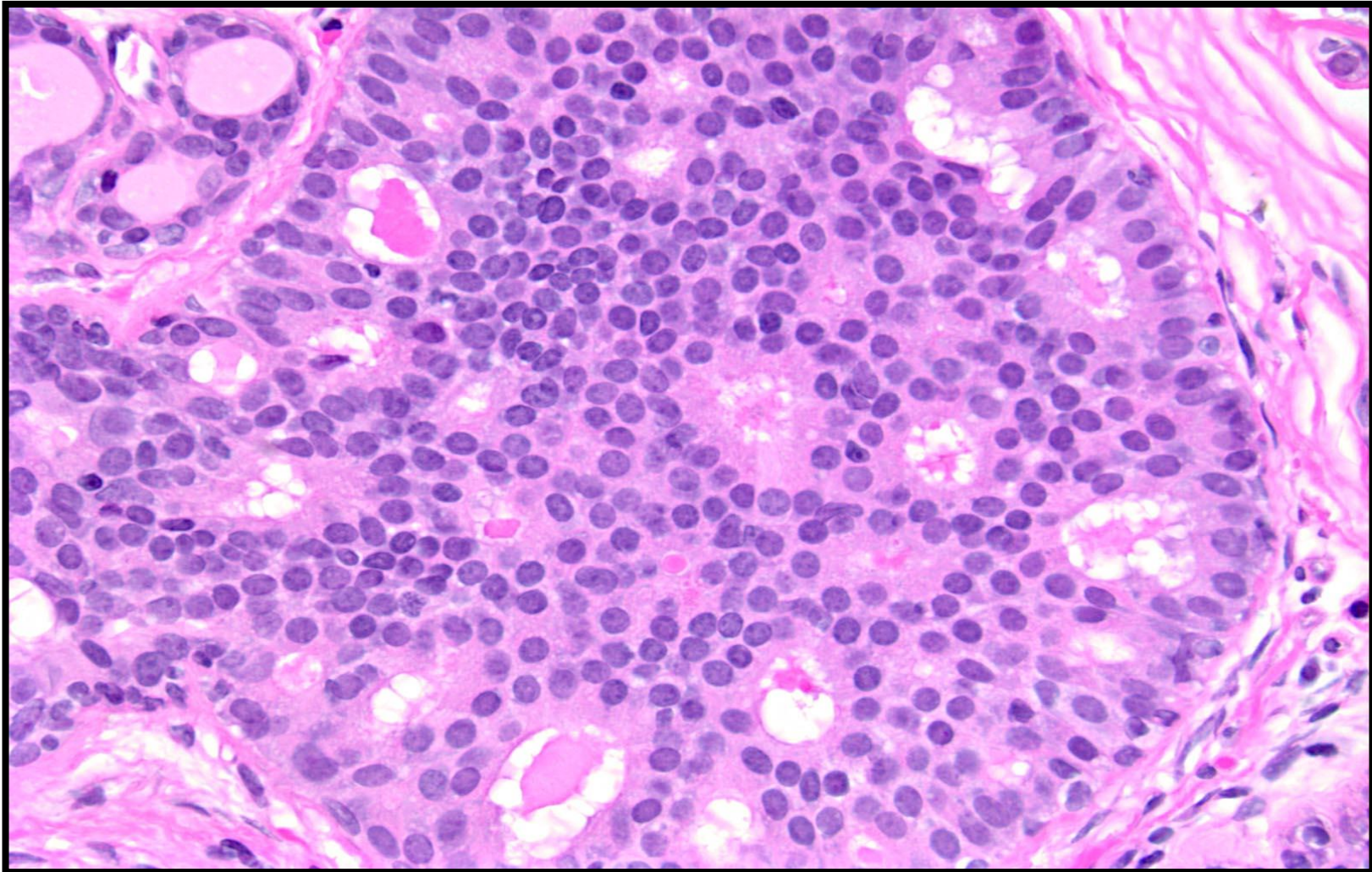
Micropapillary Hyperplasia

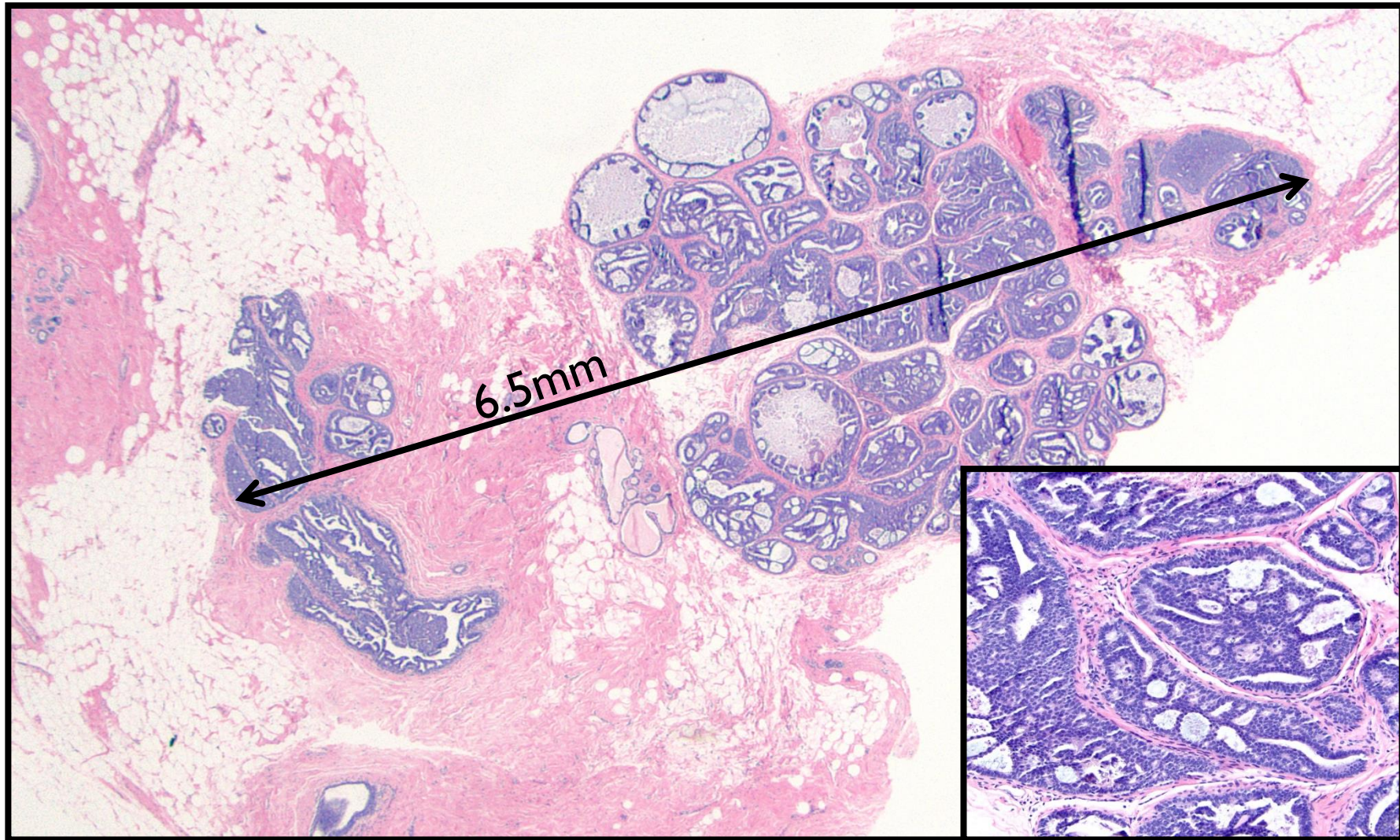




Collagenous spherulosis







ADH vs. DCIS (low nuclear grade)

Extent Criteria to Distinguish ADH from Low Grade DCIS

- Criteria developed in excisional biopsies and thresholds are arbitrary
- “WHO Classification of Tumors Editorial Board recommends a conservative approach when lesions of limited extent are identified, particularly in core needle biopsies, in which the entire lesion may not be visualized”
- Definitive categorization can be determined on excision

Elmore, JAMA, 2015

Allison, Histopathol, 2016

WHO, 2019

Extent Criteria to Distinguish ADH from Low Grade DCIS

- Because ADH falls within the spectrum from flat epithelial atypia to low-grade DCIS, diagnosis can be problematic
- Diagnostic agreement rates for ADH are low (40–60%) compared with lesions at either end of the diagnostic spectrum
- Variability in diagnosis related to differences in professional opinion/diagnostic thresholds
- Second opinions/consensus +/- IHC improve diagnostic agreement

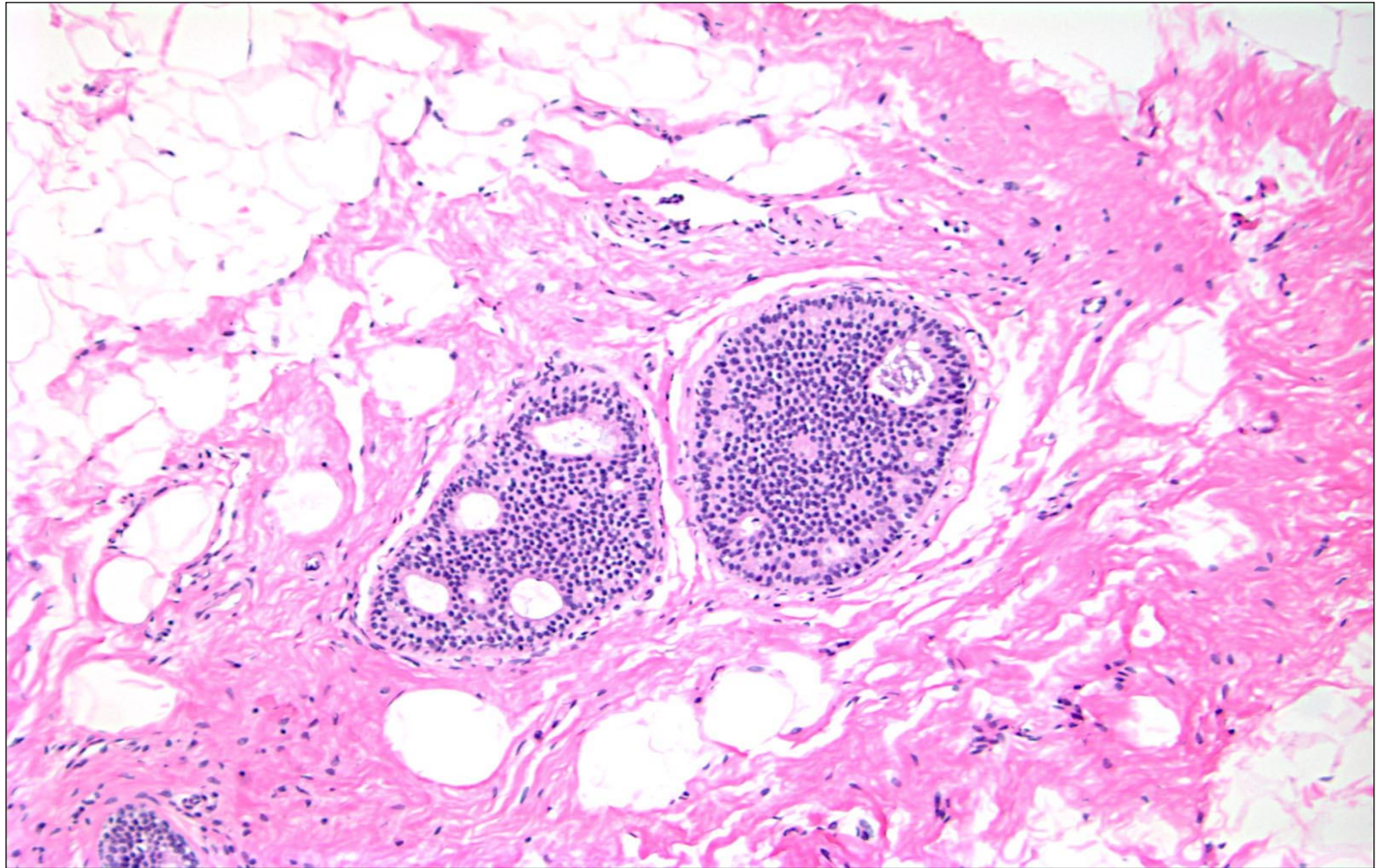
Schnitt, Am J Surg Pathol, 1992
Collins, Am J Surg Pathol, 2004
Elmore, JAMA, 2015
Allison, Histopathol, 2016
WHO, 2019

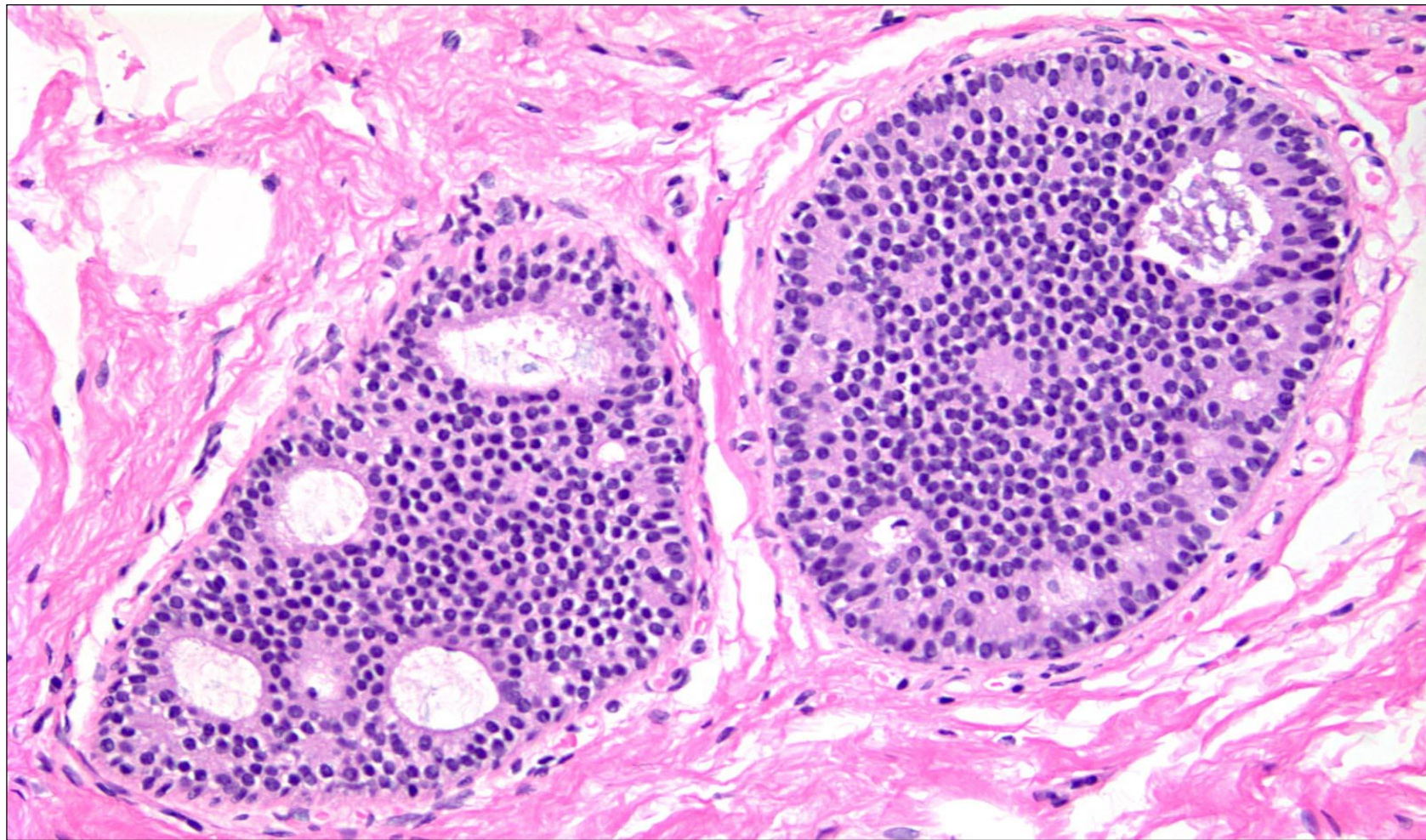
Atypical Ductal Hyperplasia

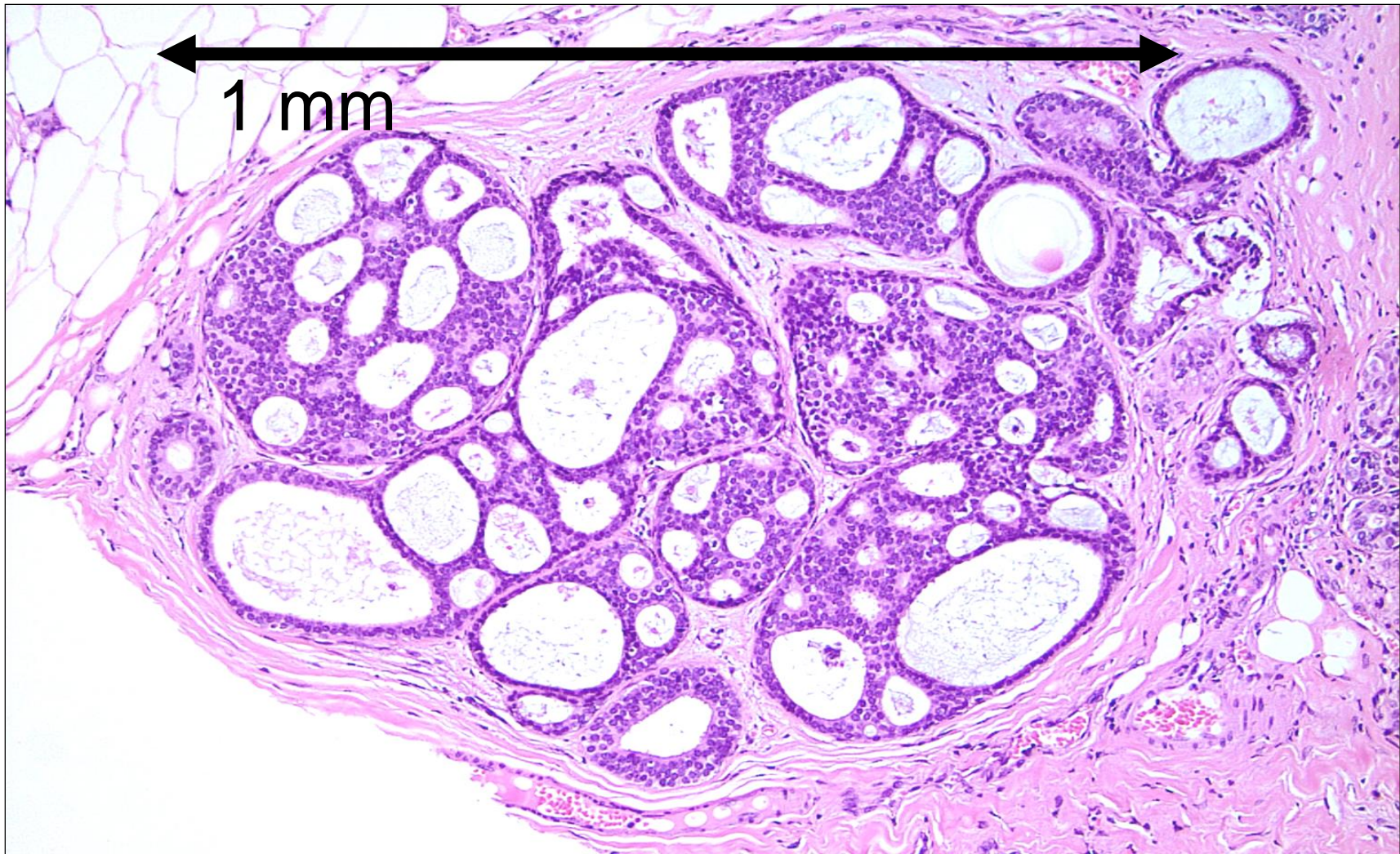
- Defined in terms of its resemblance to low grade DCIS
- Diagnosis of ADH should not be made unless a diagnosis of low grade DCIS is being seriously considered
- On CNB, a diagnosis of LG DCIS should not be rendered unless unequivocal
- Patients are increasingly opting for mastectomy or bilateral mastectomies as a therapeutic strategy following CNB Dx

ADH vs. Low Grade DCIS on CNB

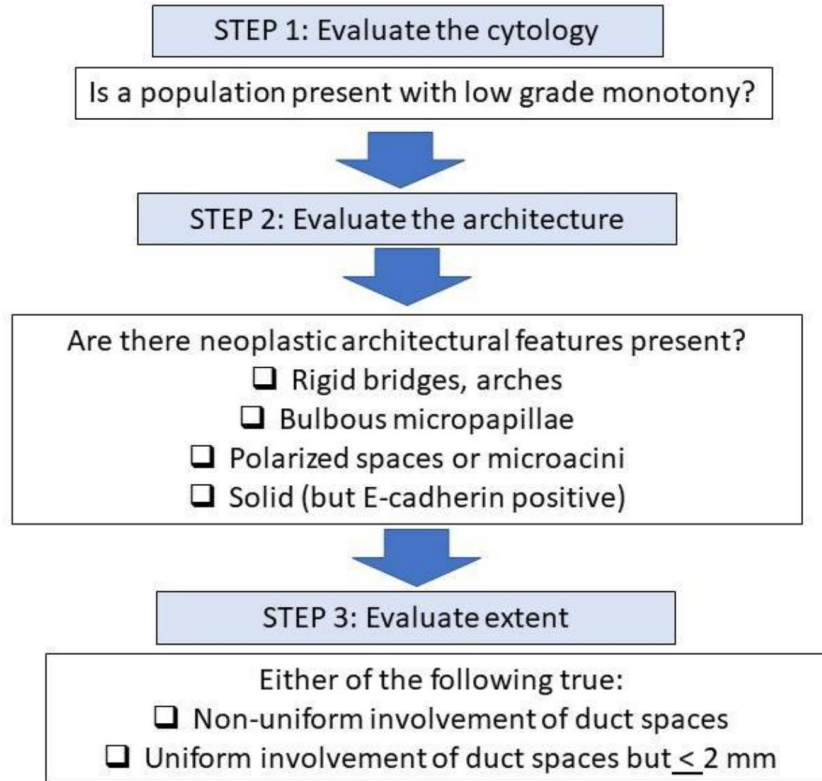
- Diagnosis of “atypical intraductal proliferative lesion” is sufficient to prompt surgical excision
- Definitive categorization based on evaluation of excision specimen
- If no further lesion, manage as ADH





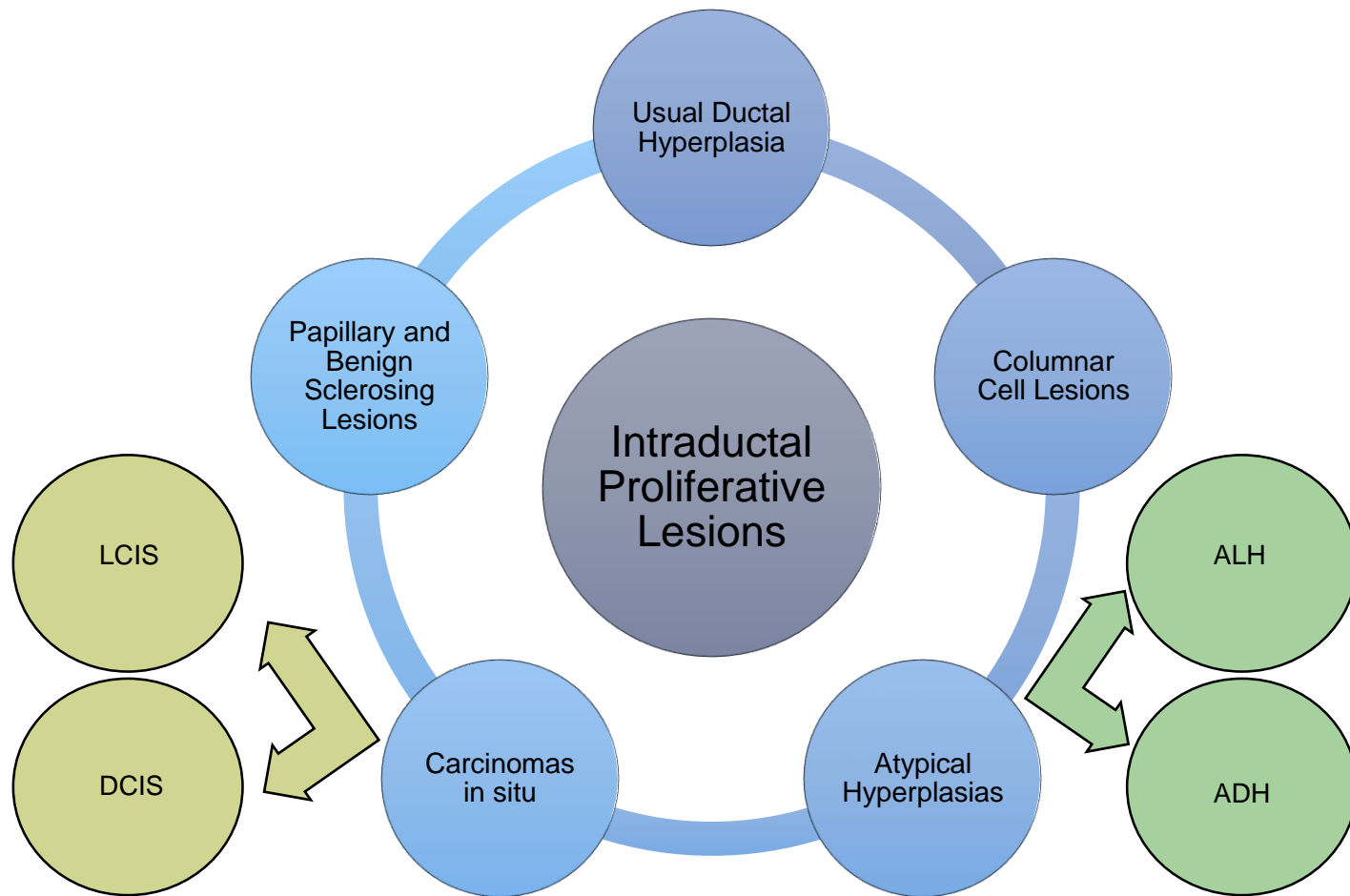


WHO Guide to Evaluation of Atypia in Intraductal Proliferations



Management Impact

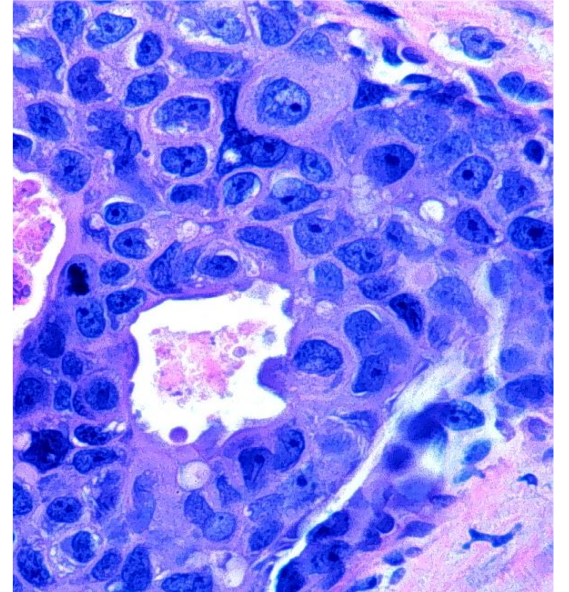
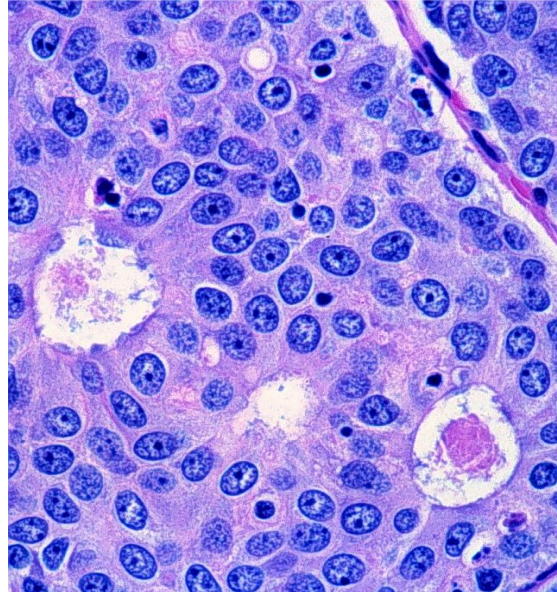
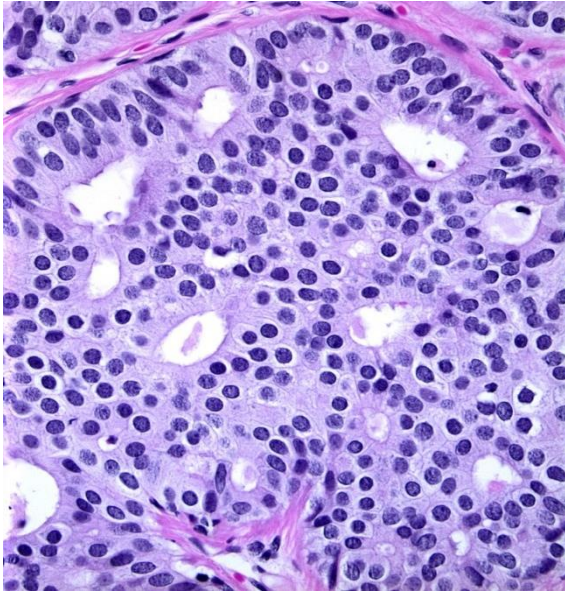
- Excision/Mastectomy/Bilateral mastectomy for DCIS
- Excision for ADH in most, though not all, institutions
- [Becomes ineligible for clinical trials for LG DCIS]



Ductal Carcinoma in Situ

Classification of DCIS

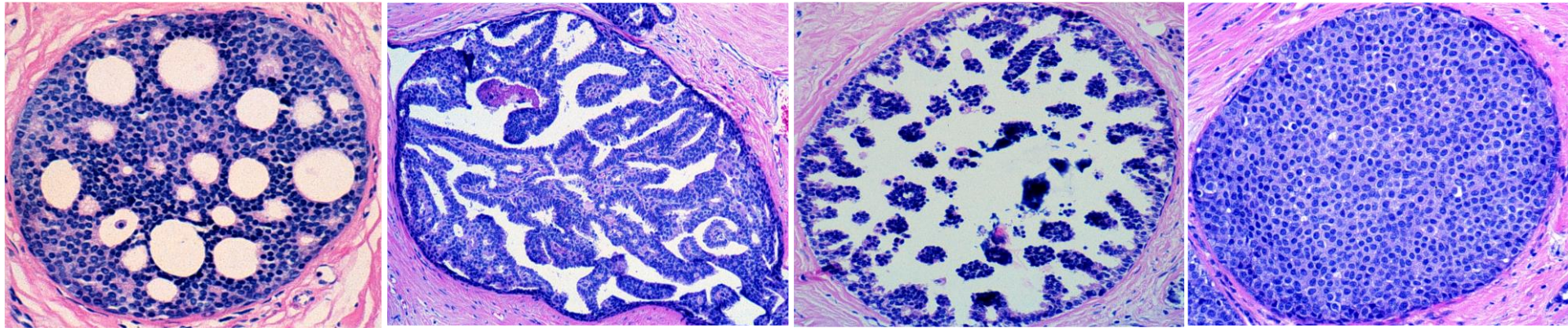
DCIS is classified according to nuclear grade



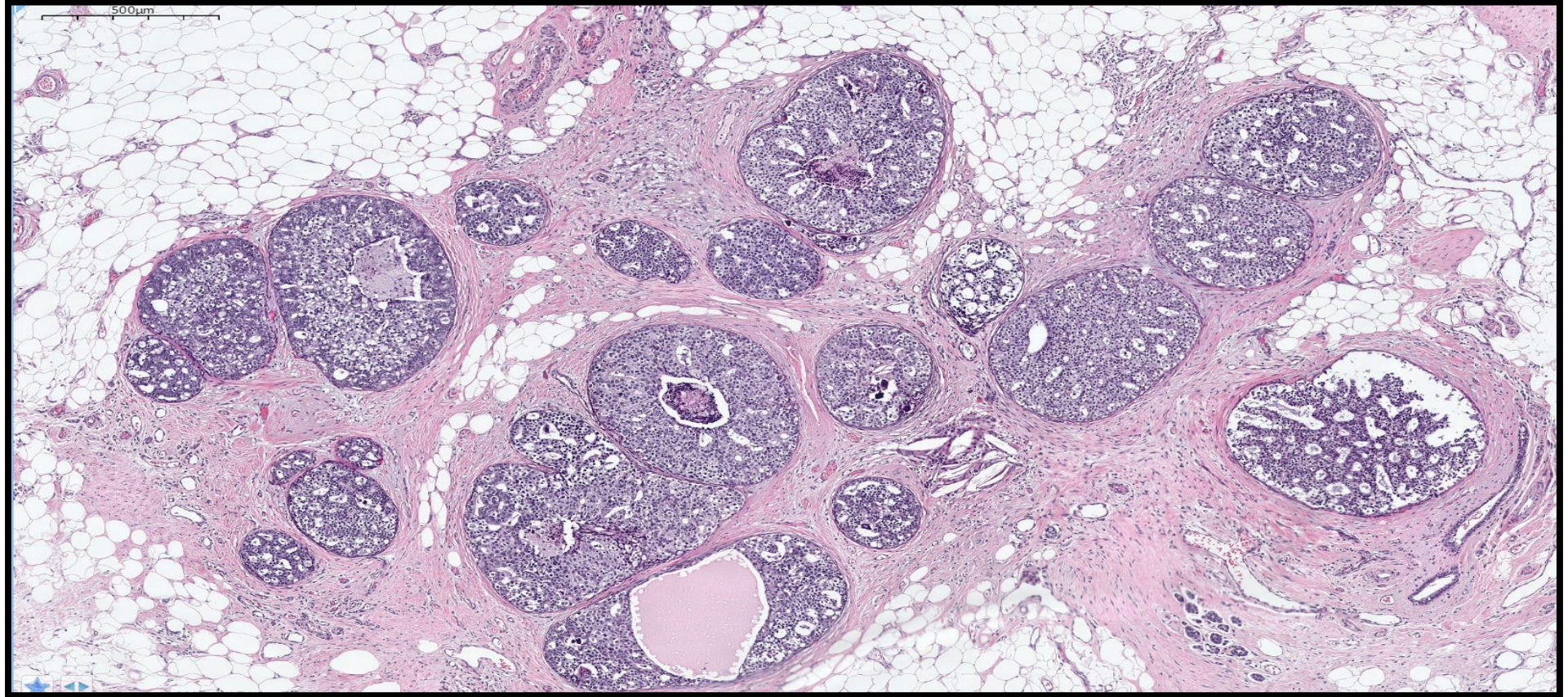
Classification of DCIS

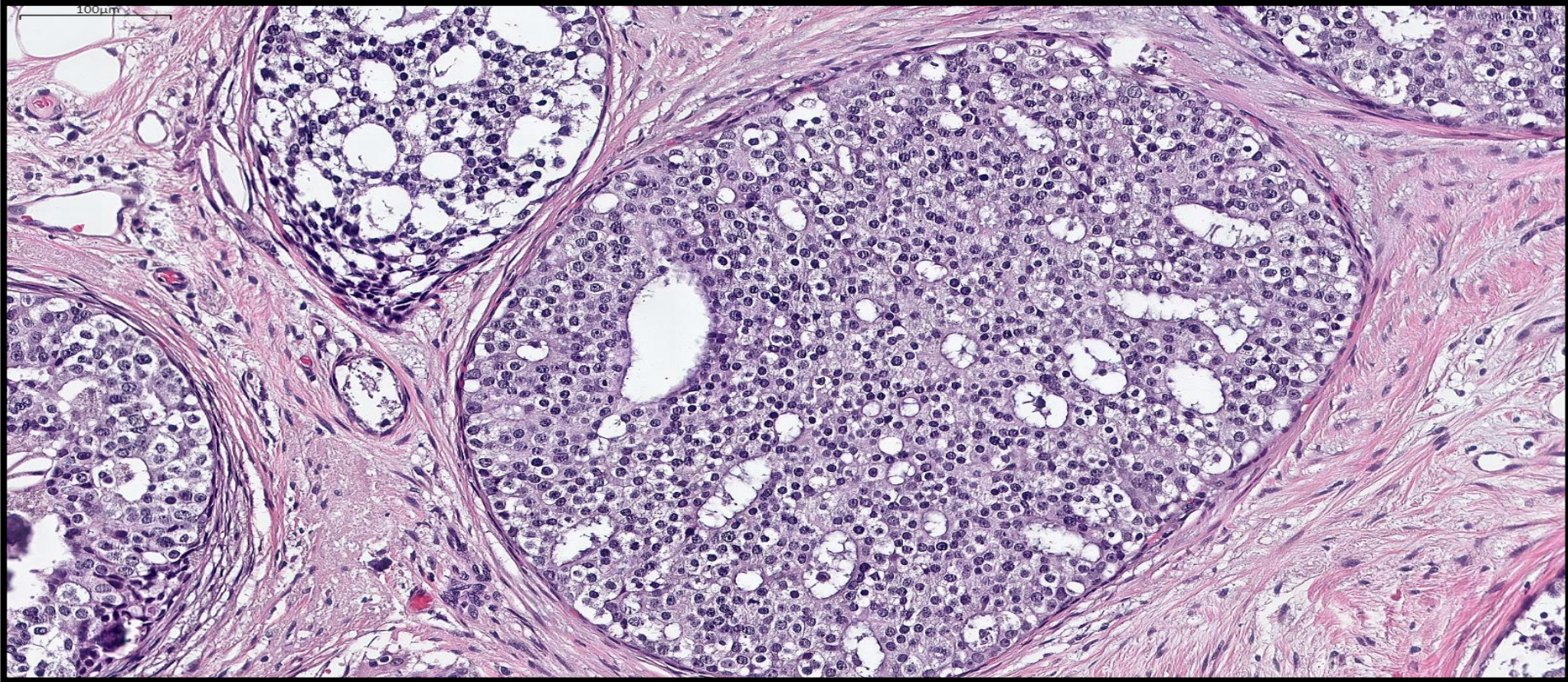
Architectural pattern and presence or absence of necrosis also noted

Comedo necrosis vs. focal necrosis not well defined



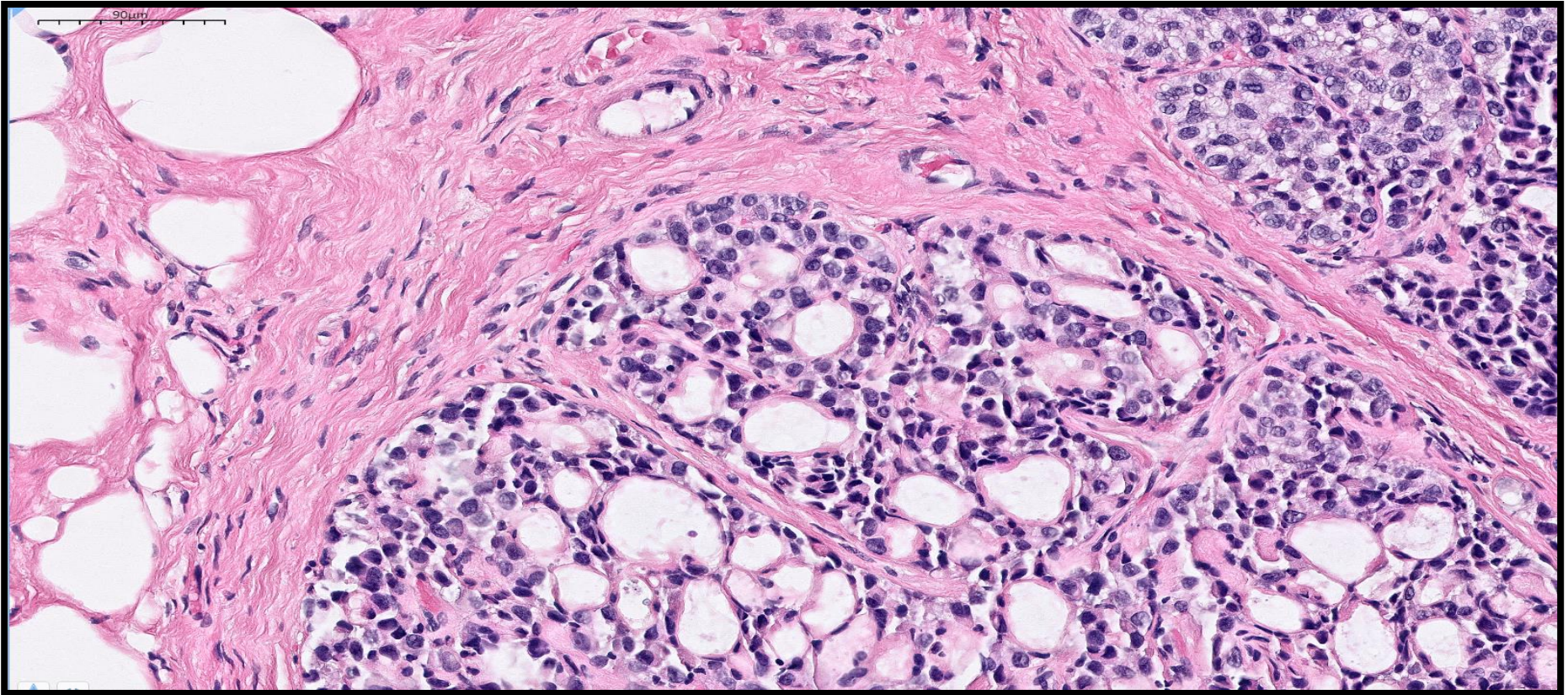
500µm



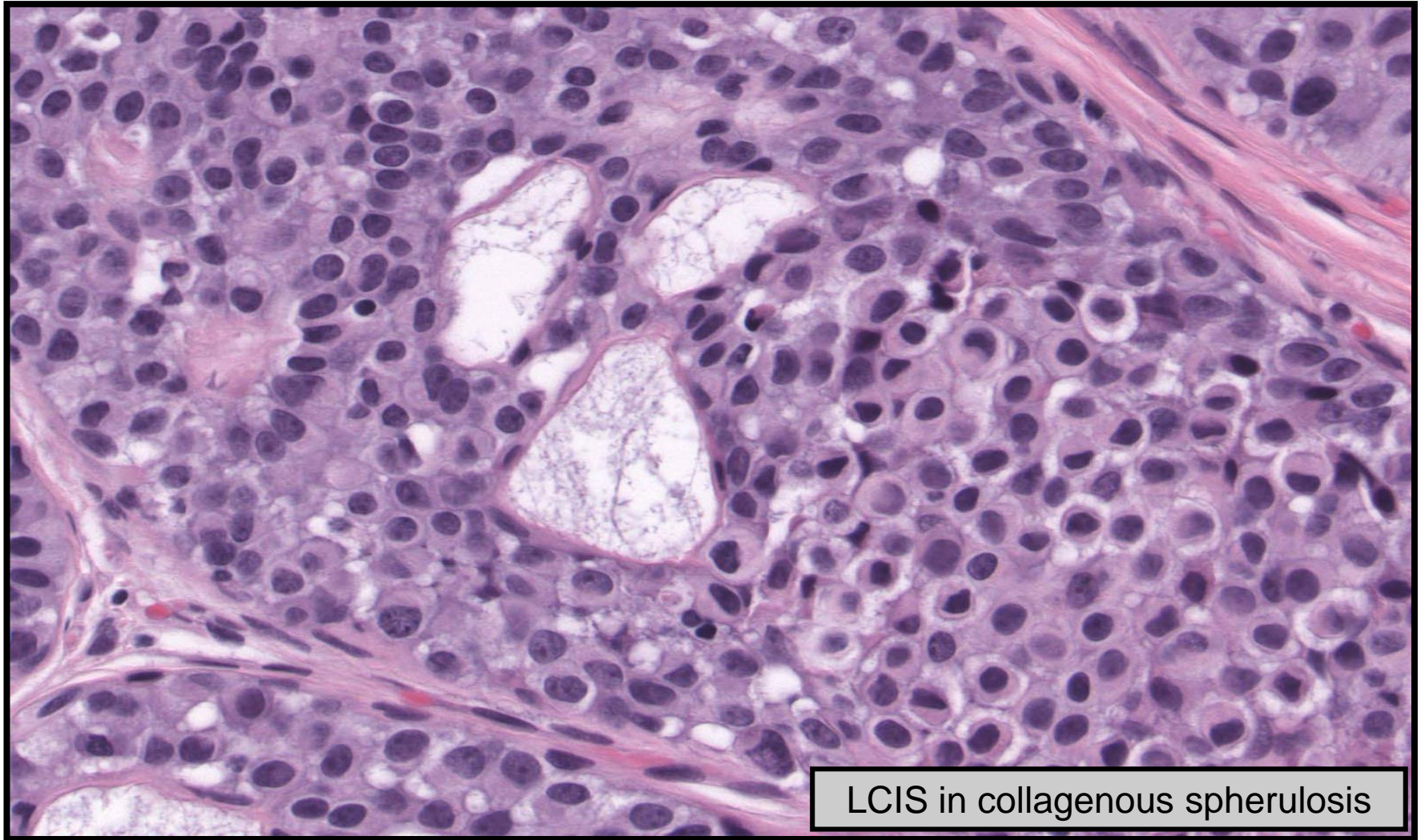


Differential Diagnosis of DCIS

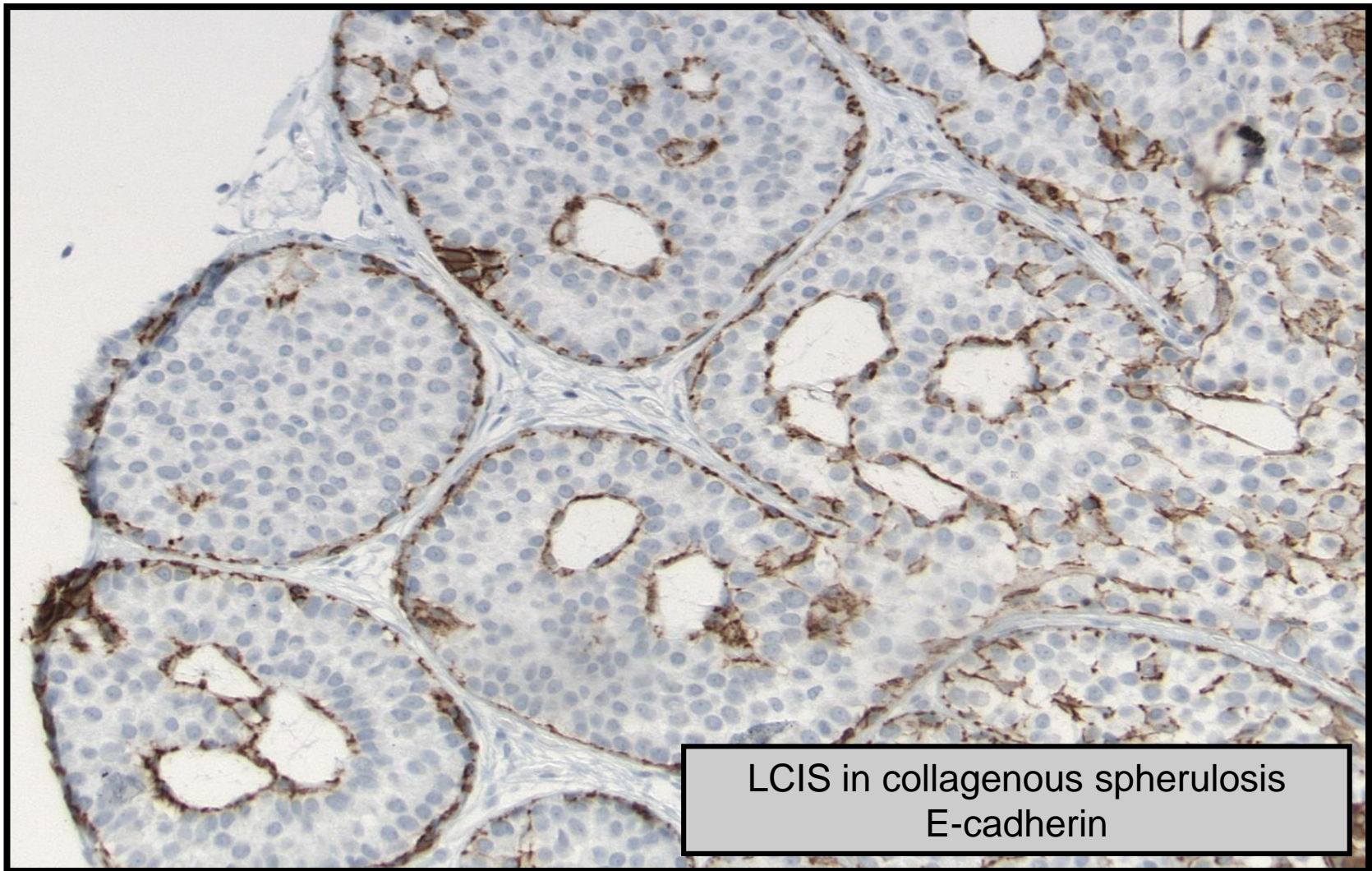
- UDH, florid and gynecomastoid
- ADH
- Collagenous spherulosis (especially with LCIS)
- LCIS (solid pattern, or florid and pleomorphic variants)
- Microinvasion
- Some invasive carcinomas (adenoid cystic, invasive cribriform etc.)
- LVI



Collagenous Spherulosis with LCIS



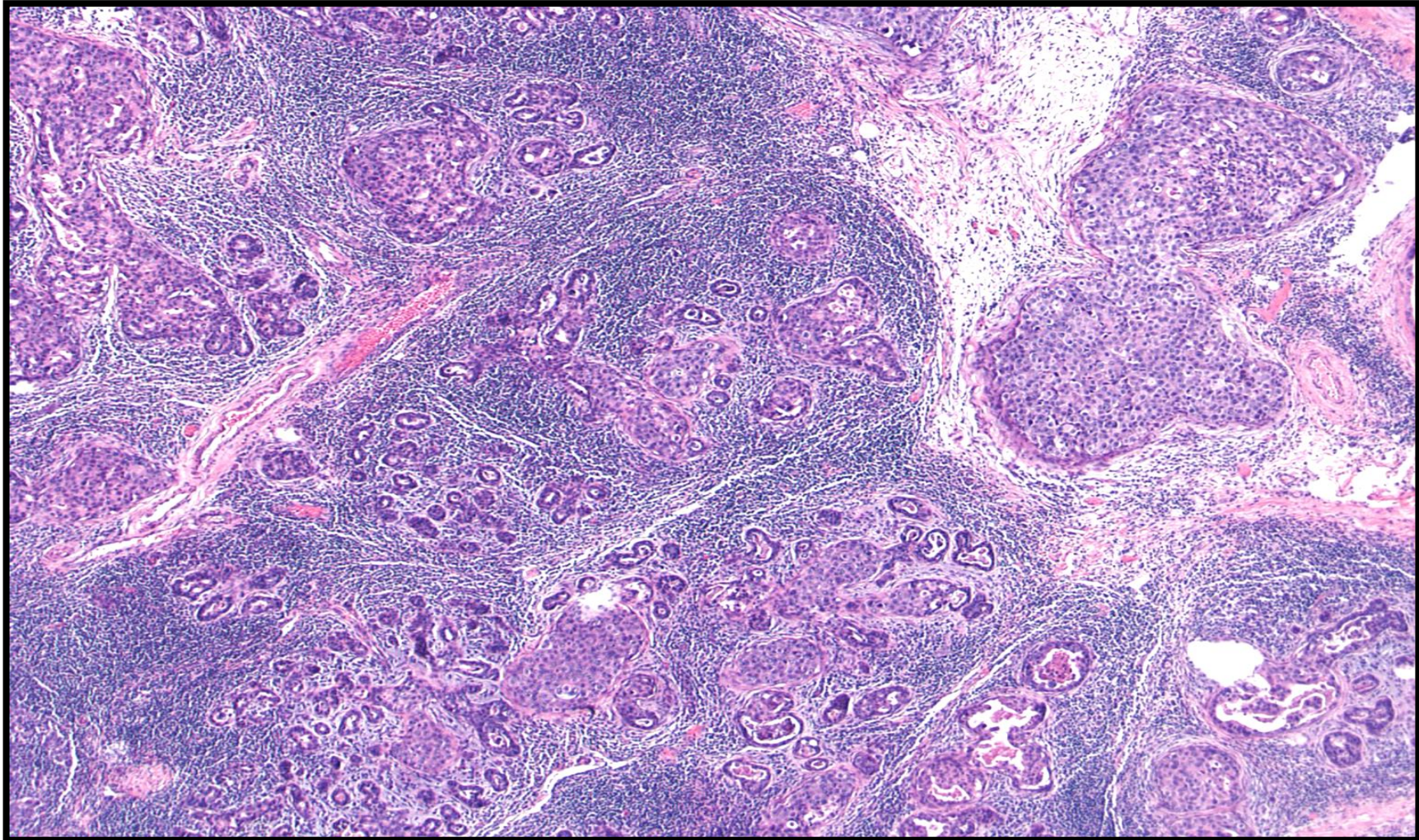
LCIS in collagenous spherulosis

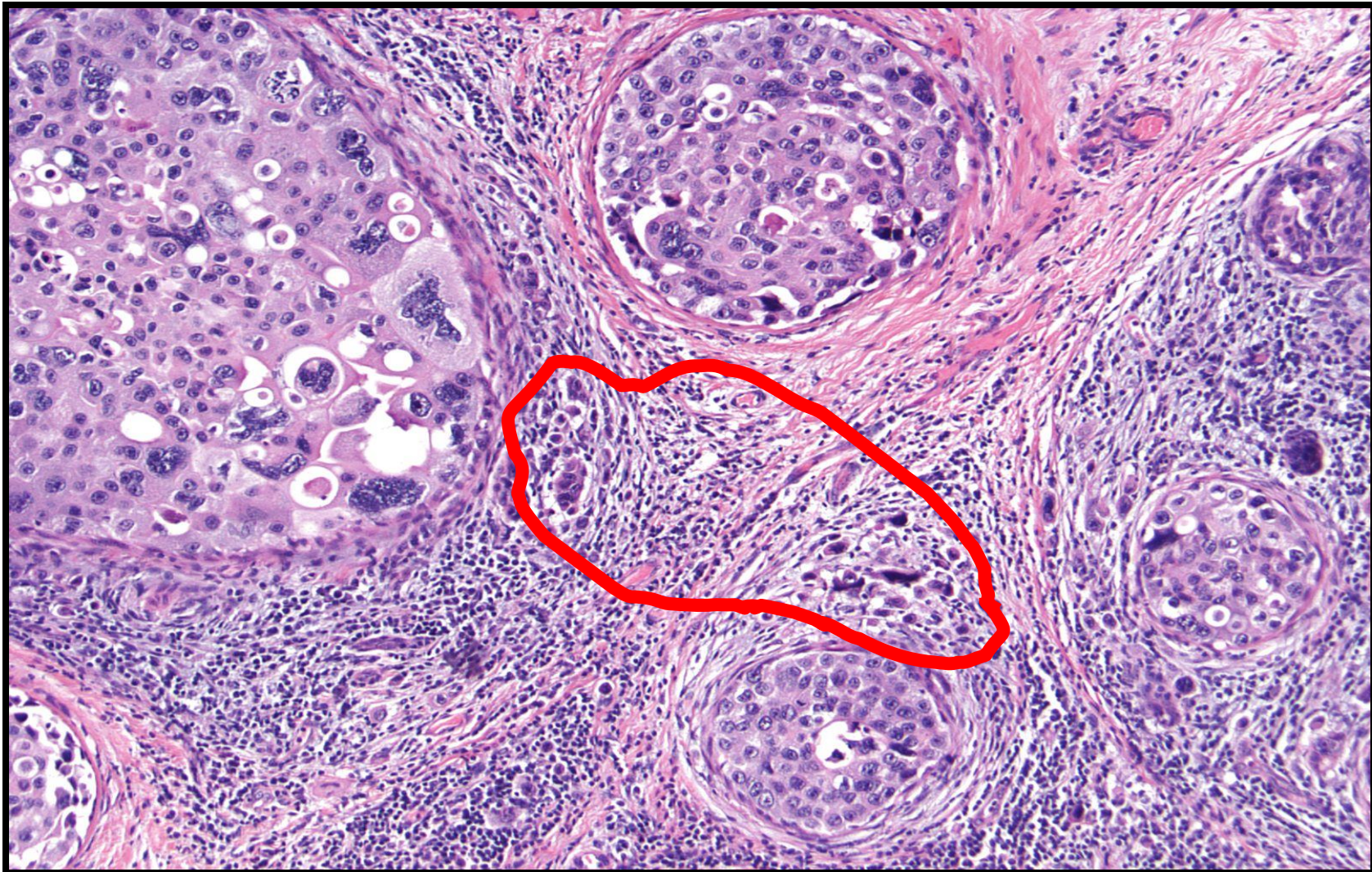


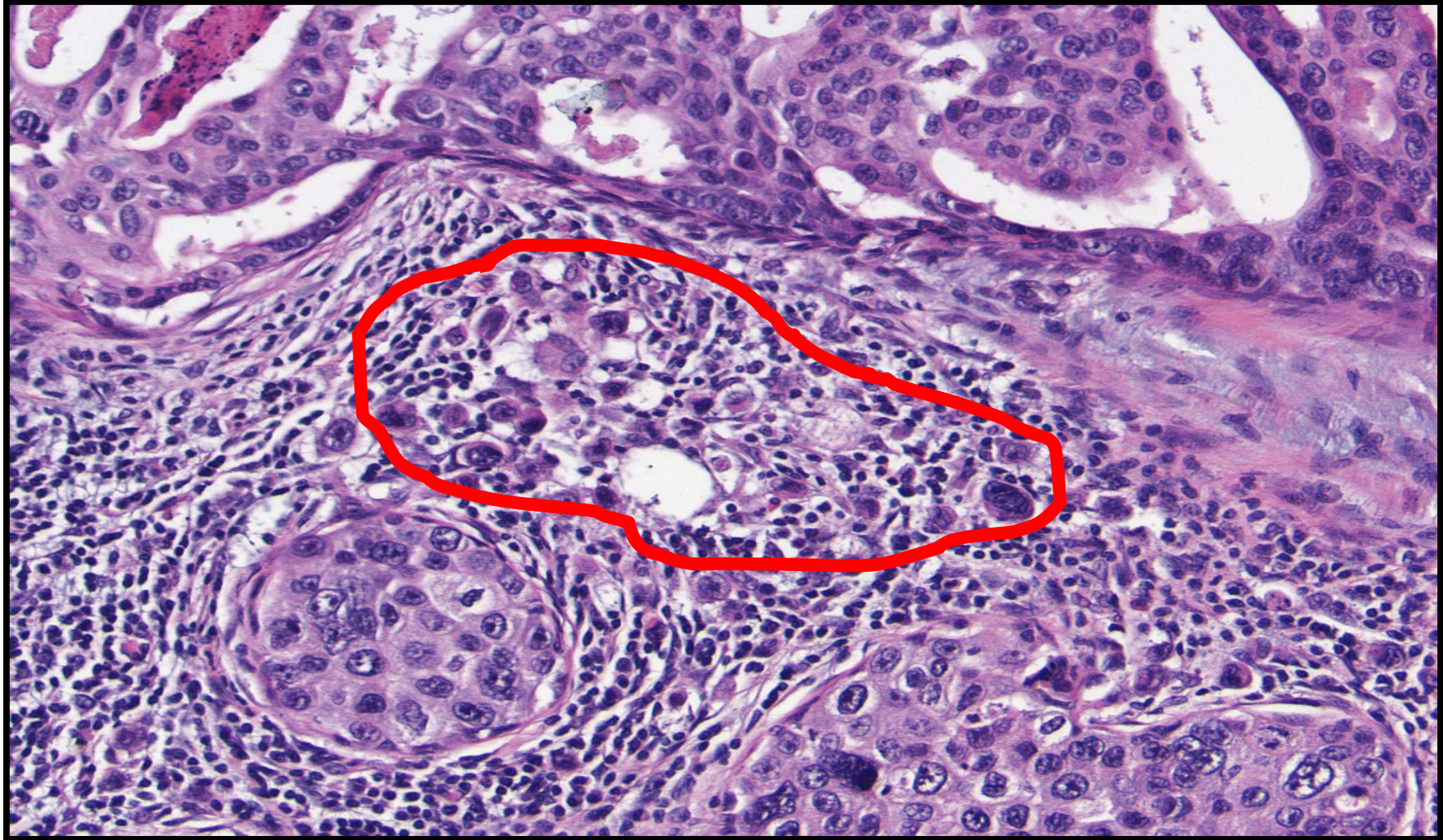LCIS in collagenous spherulosis
E-cadherin

Features of DCIS Associated with Microinvasion

- High grade/comedo histology
- May also be seen in association with other grades/types of DCIS and with LCIS
- Extent (size, number of involved ducts)
- Periductal lymphoid infiltrates





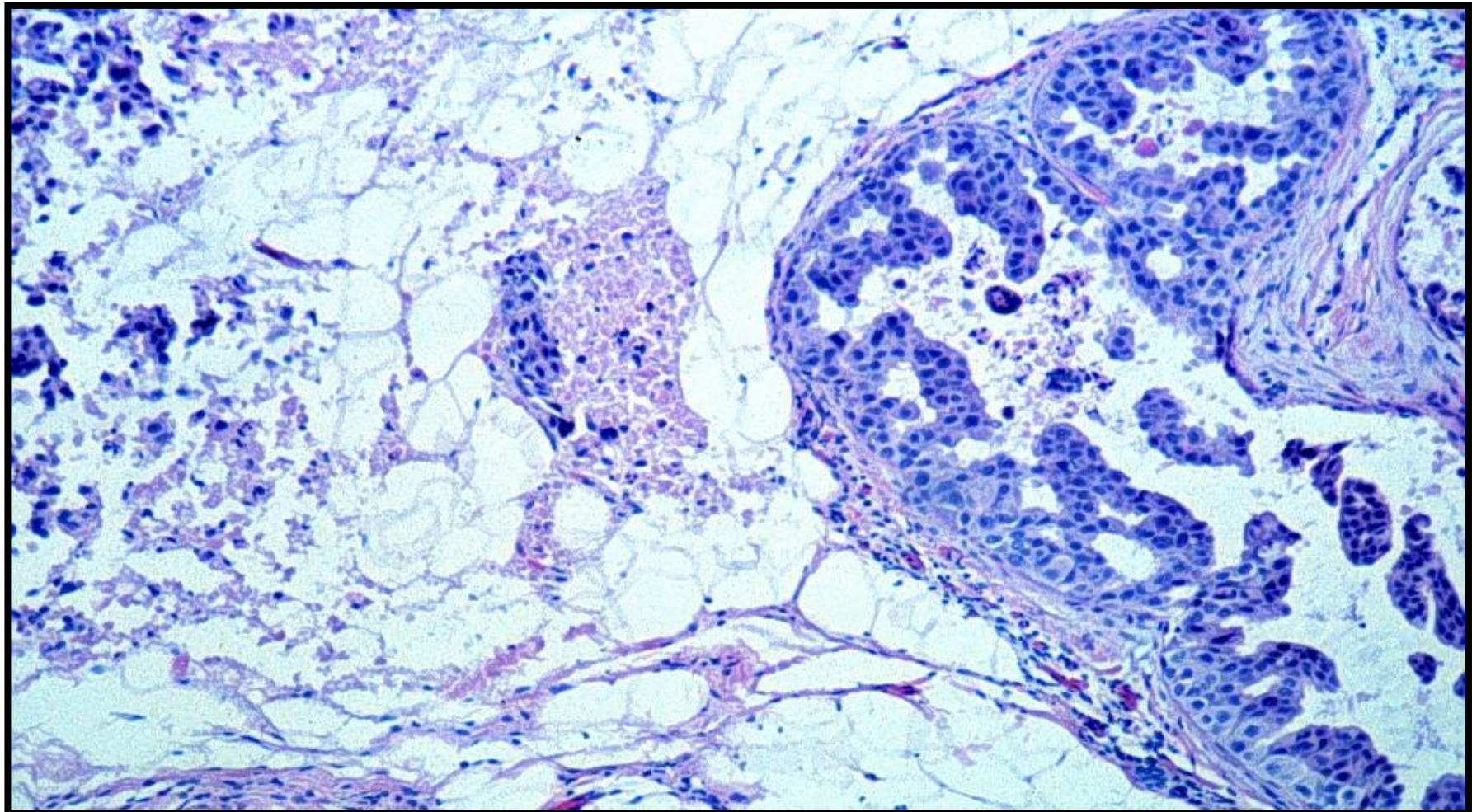


Diagnostic Difficulties with DCIS vs. Microinvasion

Over-diagnosis

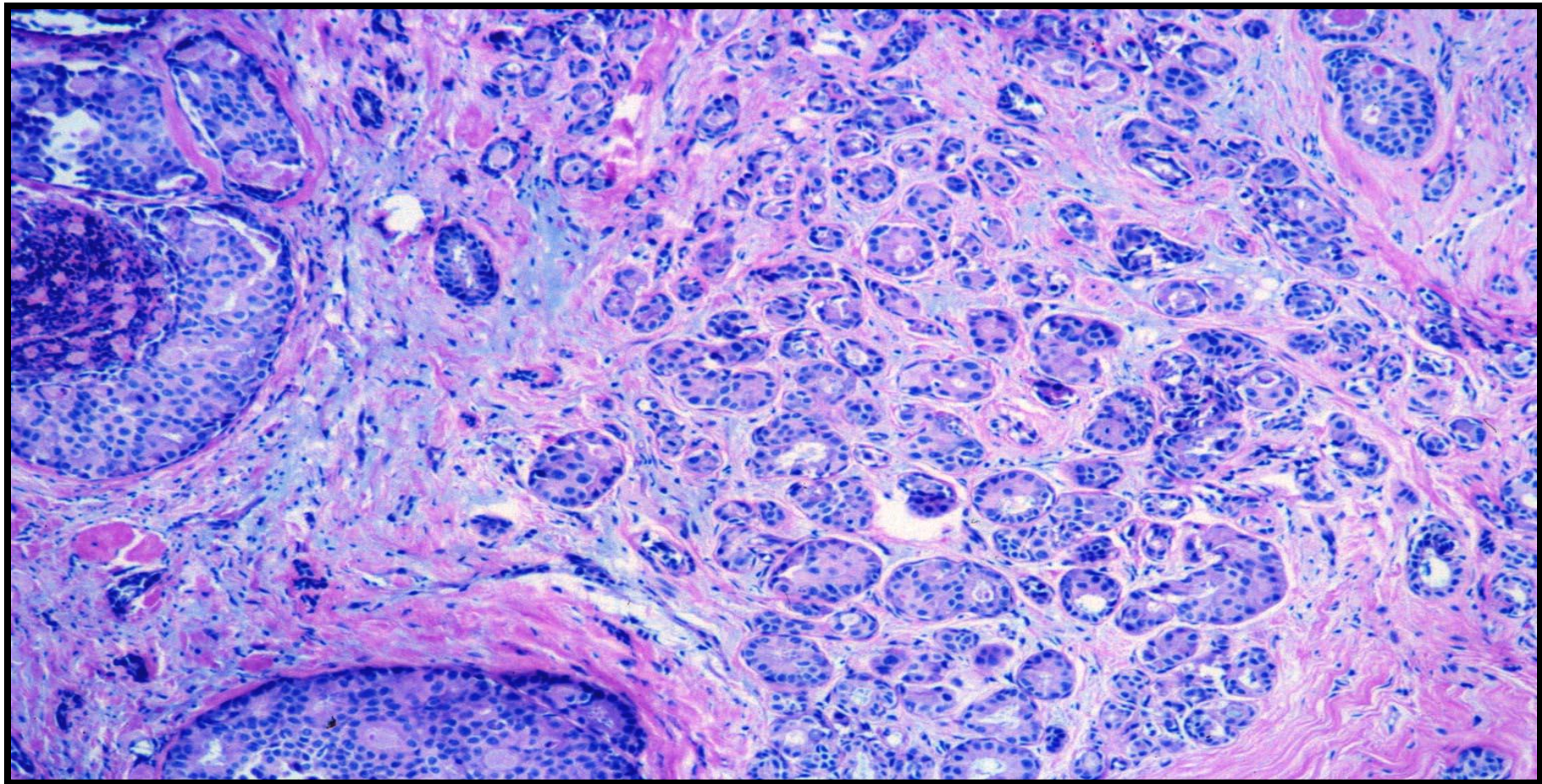
DCIS may have areas that mimic invasion

- Duct branching
- Involvement of lobules
- Involvement of benign sclerosing lesions
- Distortion of involved spaces
- Tangential sectioning
- Crush artifact
- Cautery effect
- Artifactual displacement of DCIS cells
- Defensive pathology

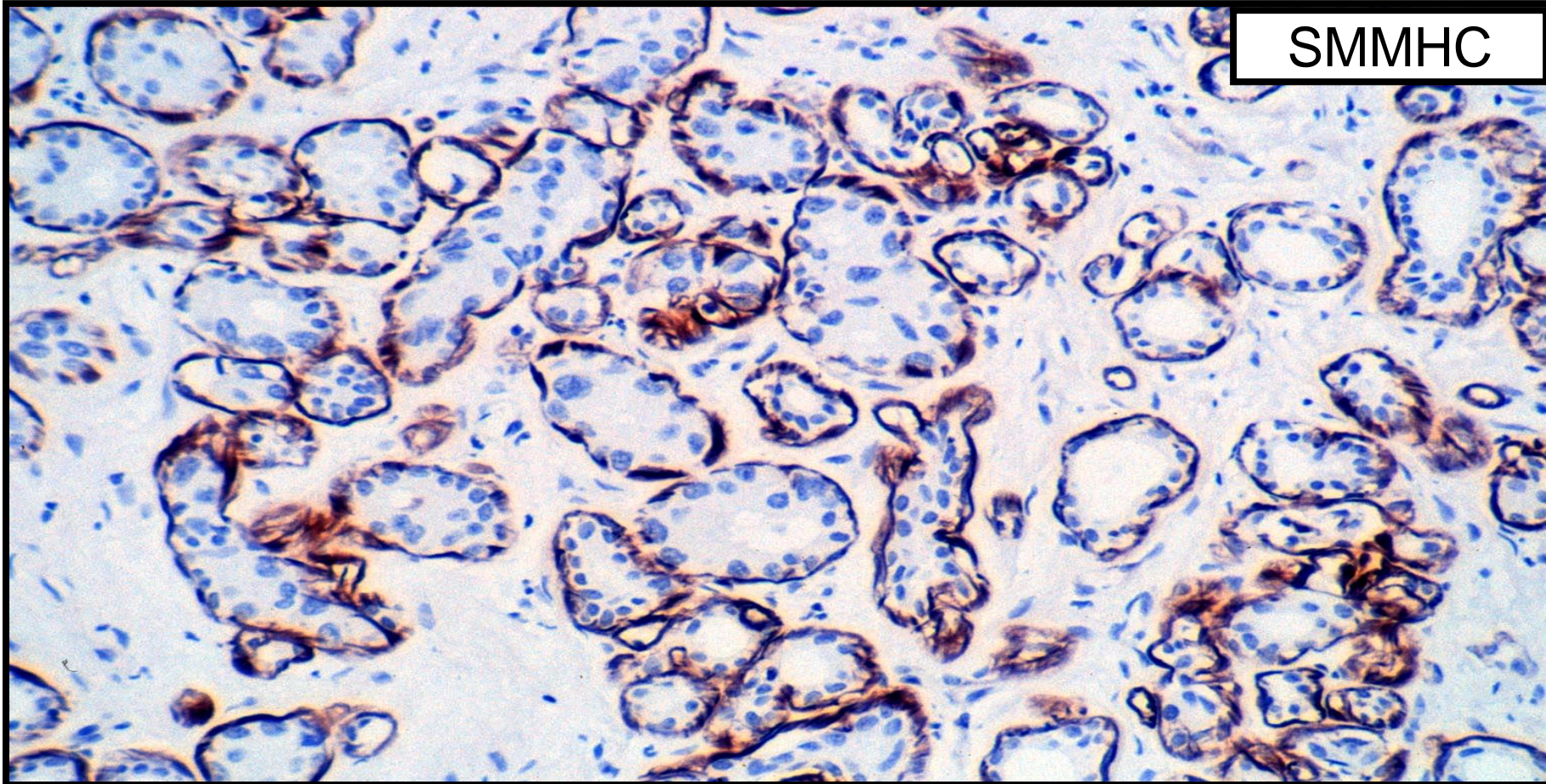


Distinction Between Mimics of Invasion and Real Invasion

- Not always possible on H&E sections, even with multiple levels
- Immunostains for myoepithelial cells



SMMHC



Diagnostic Difficulties with DCIS vs. Microinvasion

Over-diagnosis

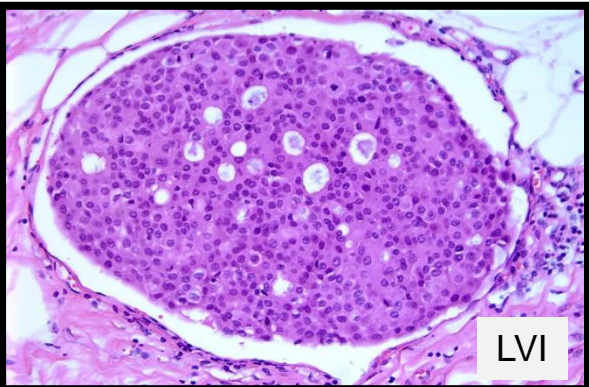
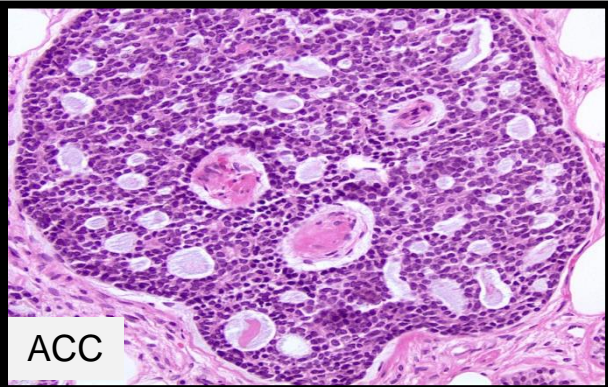
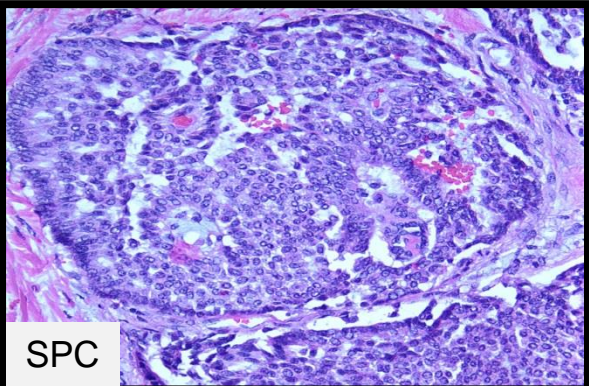
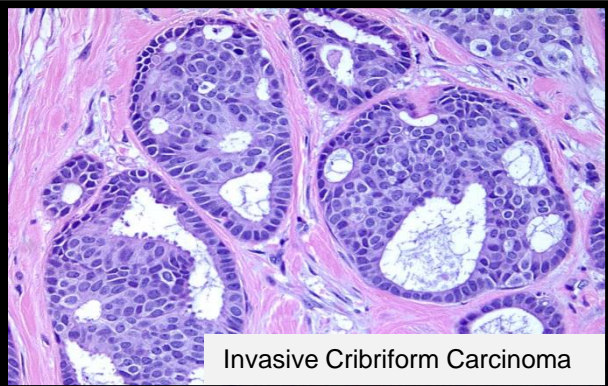DCIS may have areas that mimic invasion

- Duct branching
- Involvement of lobules
- Involvement of benign sclerosing lesions
- Distortion of involved spaces
- Tangential sectioning
- Crush artifact
- Cautery effect
- Artifactual displacement of DCIS cells
- Defensive pathology

Under-diagnosis

- Microinvasive foci may be over-looked
- Microinvasive foci may not be sampled

Other Mimics of DCIS



Invasive Mimics of DCIS

- Most mimic cribriform pattern DCIS
- Use of MEC markers can be extremely helpful in coming to the correct diagnosis
- Also useful for determining extent of invasive component

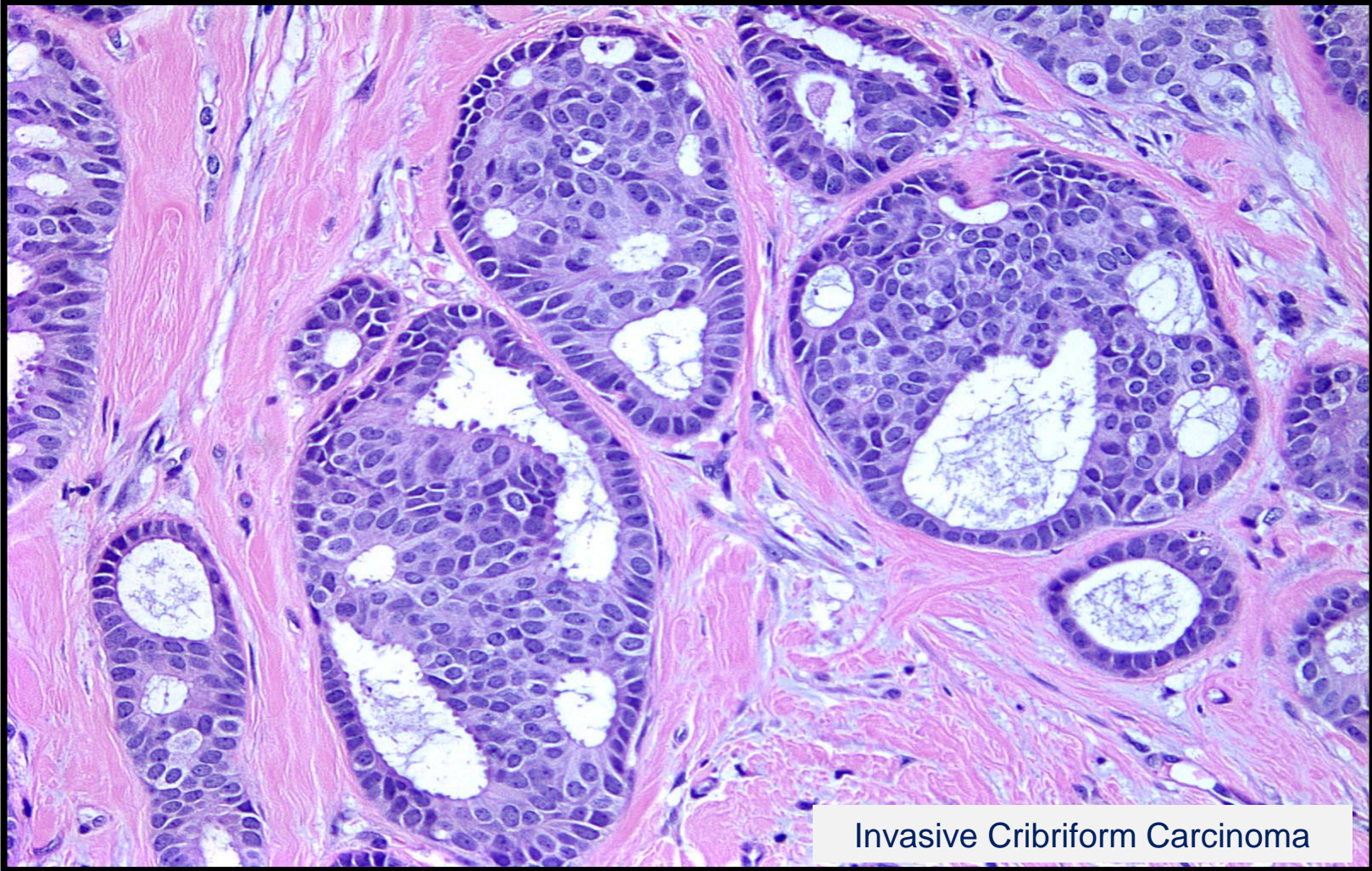
Invasive Mimics of DCIS

Invasive cribriform carcinoma

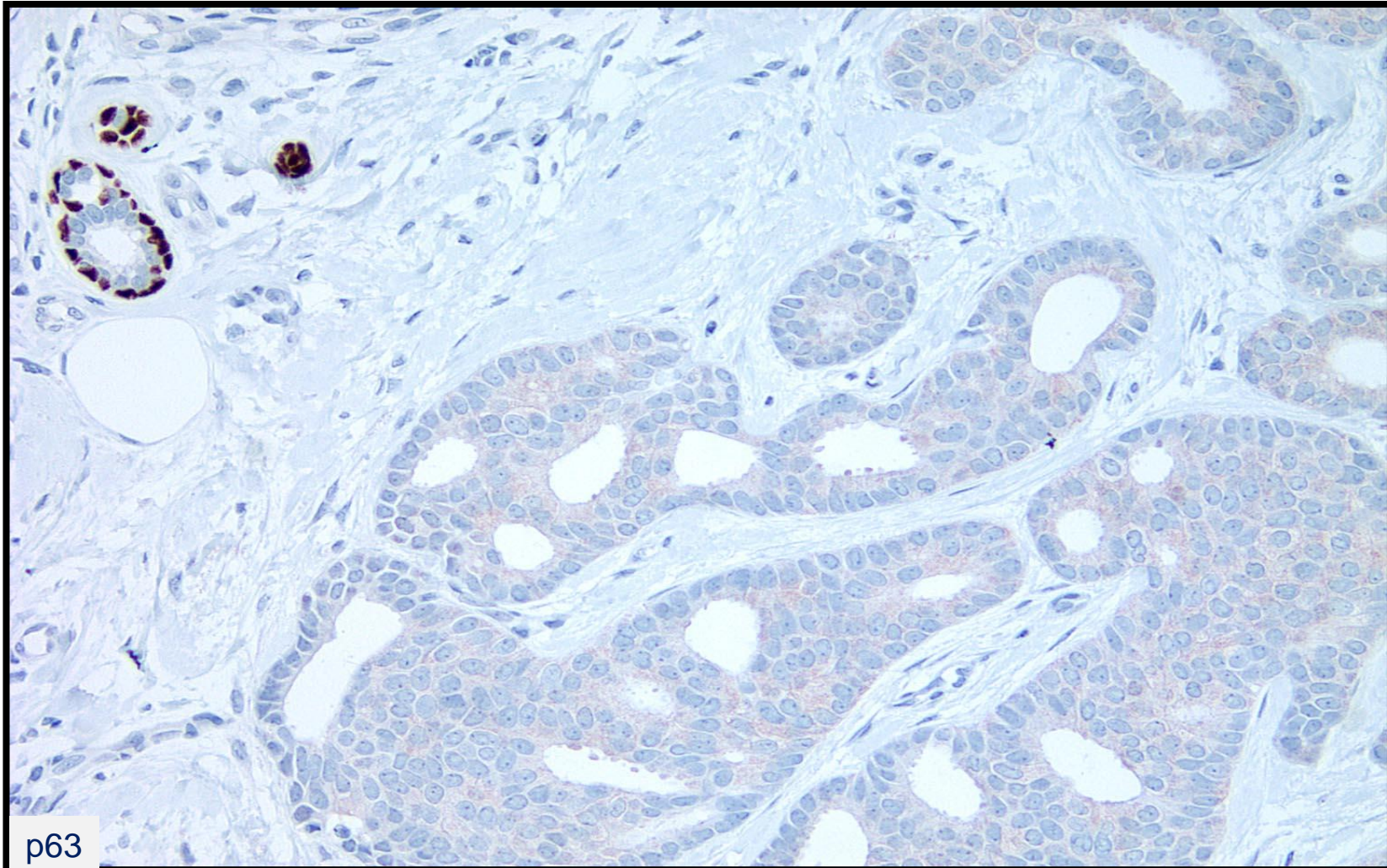
Adenoid cystic carcinoma

Invasive carcinomas in rounded nests

- Papillary carcinomas (esp, solid papillary carcinoma)
- Invasive carcinoma, NST



Invasive Cribriform Carcinoma



p63

DCIS May Mimic Invasive Carcinoma

- DCIS in adenosis or a pre-existing benign sclerosing lesion can mimic IDC, especially on CNB

CAUTION!

Some myoepithelial cell markers show reduced sensitivity for DCIS-associated myoepithelial cells (when compared to their sensitivity for normal myoepithelial cells)

Phenotypic Alterations in DCIS-associated Myoepithelial Cells

Hilson, Am J Surg Pathol, 2008

Characterization of HG DCIS with and without Regressive Changes

Chivukula, Appl Immuno Mol Morphol, 2009

Phenotypic and Functional Characterization of DCIS-associated Myoepithelial Cells

Rohilla, Clin Breast Cancer, 2015

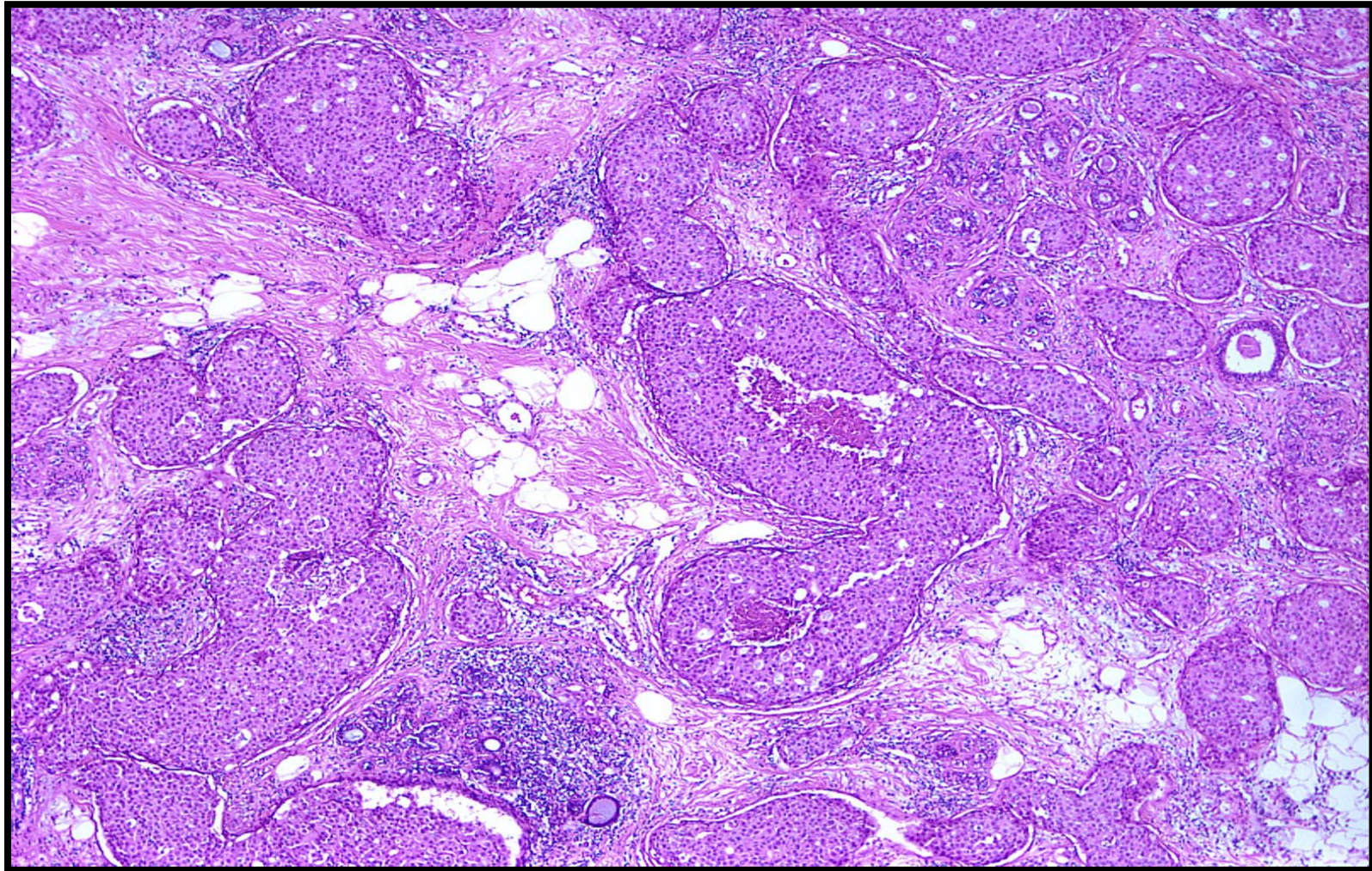
Demonstration of reduced expression of SMMHC in DCIS-associated MECs

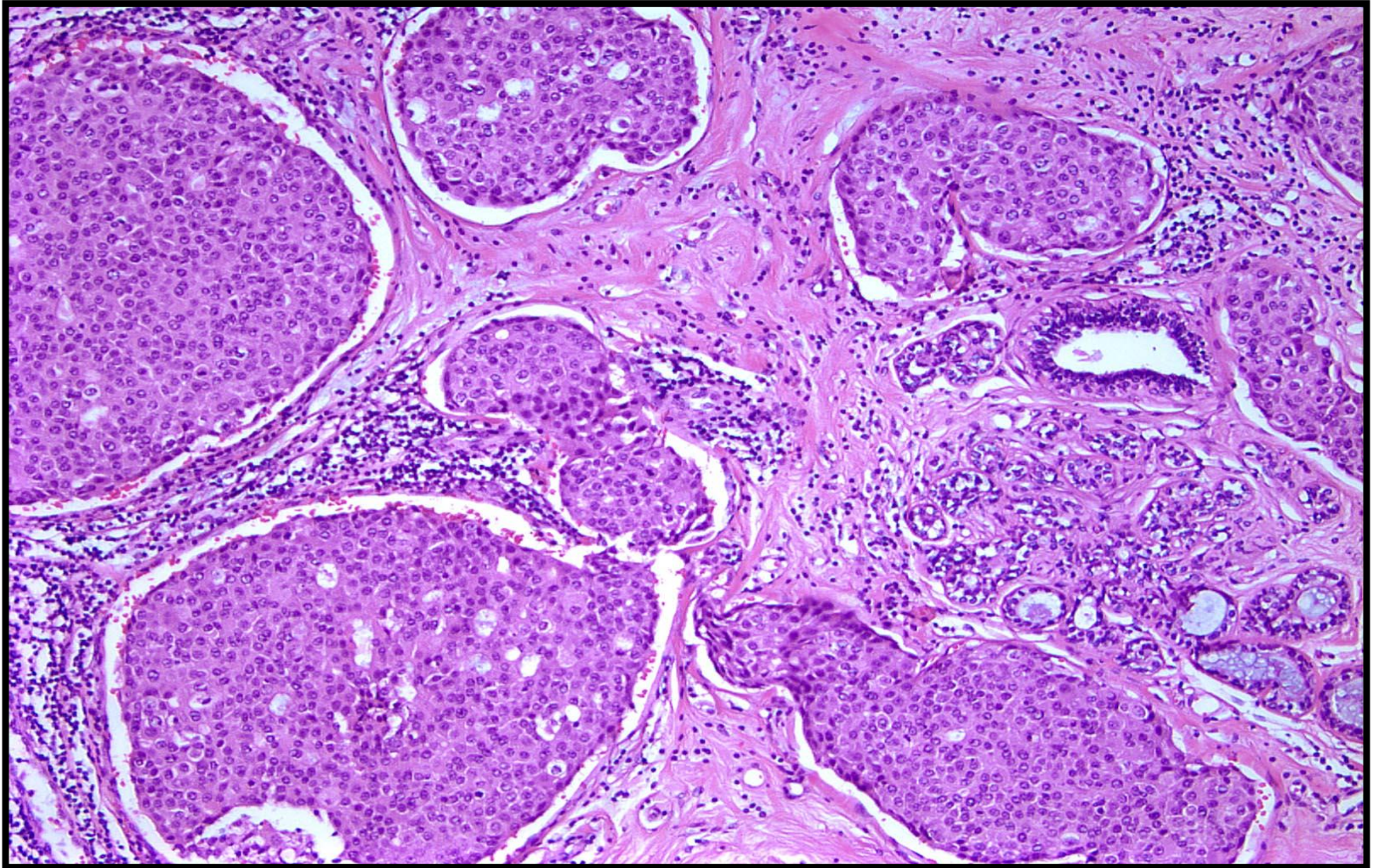
Demonstrated reduced expression of p63 and SMMHC in HG DCIS with *regressive changes* (periductal fibrosis and dense lymphoid infiltrates)

Reduced expression of CK14, p63, calponin and maspin in DCIS-associated MECs

Practical Implications

- DCIS-associated MEC have immunophenotypic differences from normal MEC
- Sensitivity of MEC markers for DCIS-associated MEC varies and differs from their sensitivity for normal MEC
- Always use a panel of antibodies





LVI Mimicking DCIS

Helpful clue: Pattern of cell nests conforms to location of normal lymphovascular spaces rather than structure of ductal-lobular system

- Vascular bundles
- Periductal
- Interlobular stroma
- Try to assess relationship of worrisome nests to identifiable ducts and lobules
- Remember D240 cross reacts with MECs (use a panel)

Management of Intraductal Proliferative Lesions

Beth Israel Lahey Health 

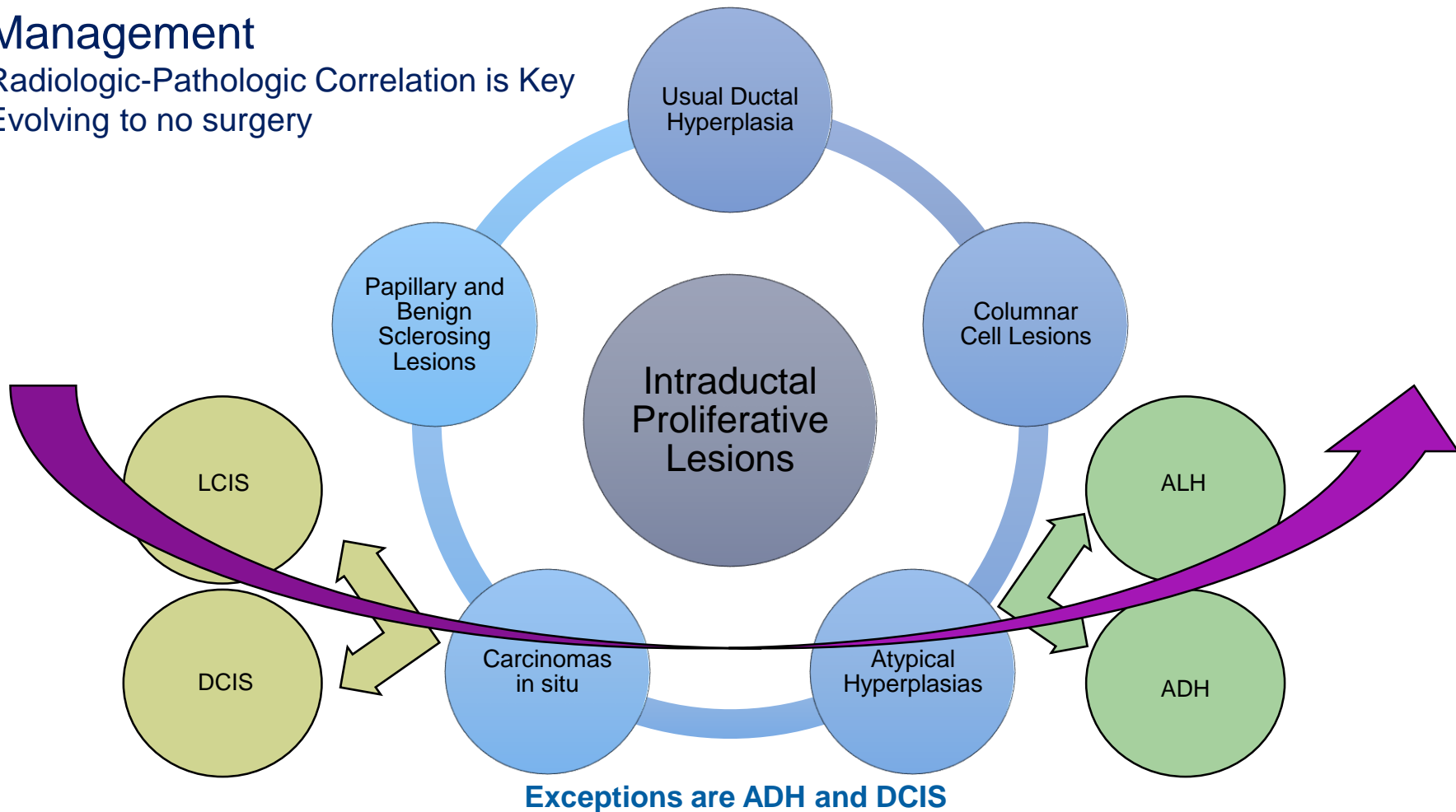
Beth Israel Deaconess
Medical Center



HARVARD MEDICAL SCHOOL
TEACHING HOSPITAL

Management

Radiologic-Pathologic Correlation is Key
Evolving to no surgery



Core Needle Biopsy

UDH/CCL

No further treatment for UDH/CCC/CCH

Evolving for FEA, but moving toward no excision if there is good rad/path correlation

Benign Sclerosing Lesions and Papillomas

Evolving for CSLs, but beginning to move toward no excision if there is good rad/path correlation

Excision for symptomatic papillomas

No excision for incidental lesions

ALH and classic LCIS

Excision *not* required for incidental rad/path concordant lesions

ADH

Excision is current standard of care in the USA

Not so in Europe

Difference in management algorithms has resulted in different diagnostic thresholds in Europe compared with our practice in the US

Paradoxically, trials are being initiated for active surveillance of DCIS, but ADH is currently still excised when diagnosed on CNB

DCIS

Current standard of care is excision

Active surveillance clinical trials in progress for LG DCIS

Enrollment has been a challenge due to women wishing to opt for observation arm once learning of the risks (not willing to be randomized to surgery)

Excision Specimens

UDH/CSL/CCL

No further treatment

ADH and LN

Observation

+/- Chemoprevention

DCIS

Complete local eradication

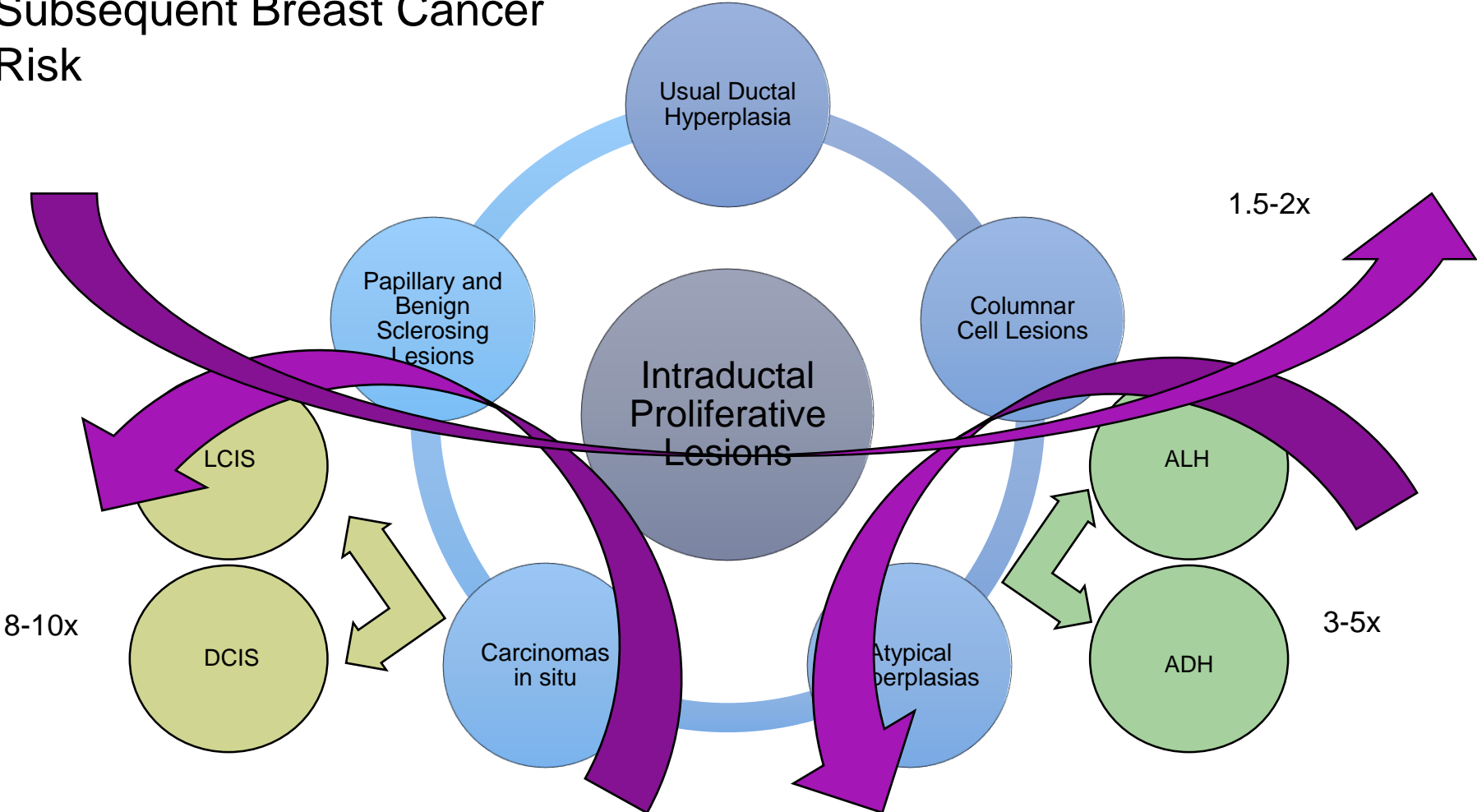
Clear margins

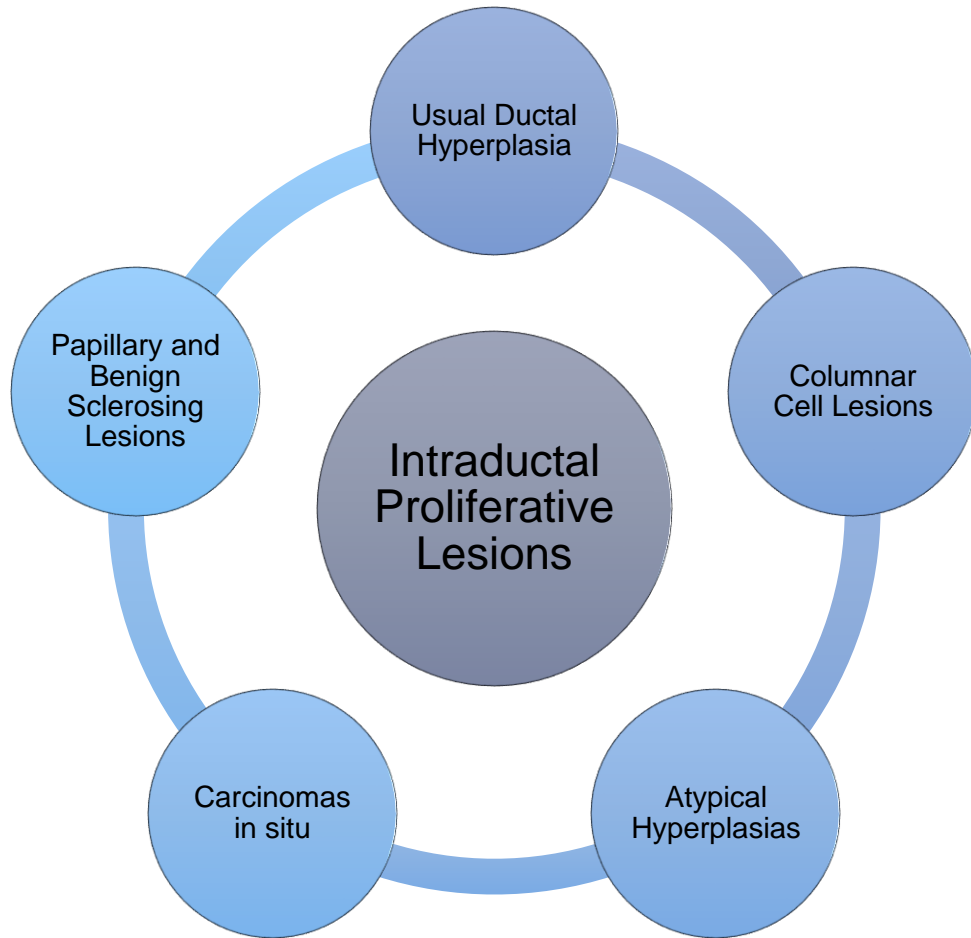
+/- Radiation

Chemoprevention

New trials evaluating
outcomes with active
surveillance alone

Subsequent Breast Cancer Risk





Summary

Discussed histologic features, differential diagnoses and diagnostic difficulties associated with intraductal proliferative lesions

Reviewed the distinguishing IHC panels for difficult ductal proliferations

Discussed the current management strategies

THANK YOU!